# Anatomy of Digestive System

## Small and Intestines, Liver, Pancreas

**Prof Dr Mohamed El-Badry Mohamed**

**Professor and Head of Human Anatomy and Embryology Department, Faculty of Medicine, Merit University**

**Professor of Human Anatomy and Embryology Department, Faculty of Medicine, Assiut University**

# Objectives of the of the Lecture

**By the end of the lecture the student should be able to:**

- Mention the organs forming the gastrointestinal tract

- Describe anatomy of the duodenum?

- What are the differences between ilium and jejunum?

- Mention differences between small and large intestine?

- Describe anatomy of the large intestine

# SMALL INTESTINE

- Longest part of alimentary canal
- Extends from pylorus of stomach to ileocecal junction

**Divides into 3 parts:**

1. Duodenum
2. Jejunum
3. Ileum

# DUODENUM

## LOCATION AND DESCRIPTION:

- ❖C-shaped tube about 10 inches (25 Cm) long
- ❖Joins stomach to jejunum
- ❖Situated in epigastric and umbilical regions
- ❖Curves around head of pancreas

1st inch of duodenum:

- ➢Covered on its anterior and posterior surfaces with peritoneum
- ➢Has lesser omentum attached to its upper border and lesser sac lies behind it

- Remainder of duodenum is retroperitoneal.

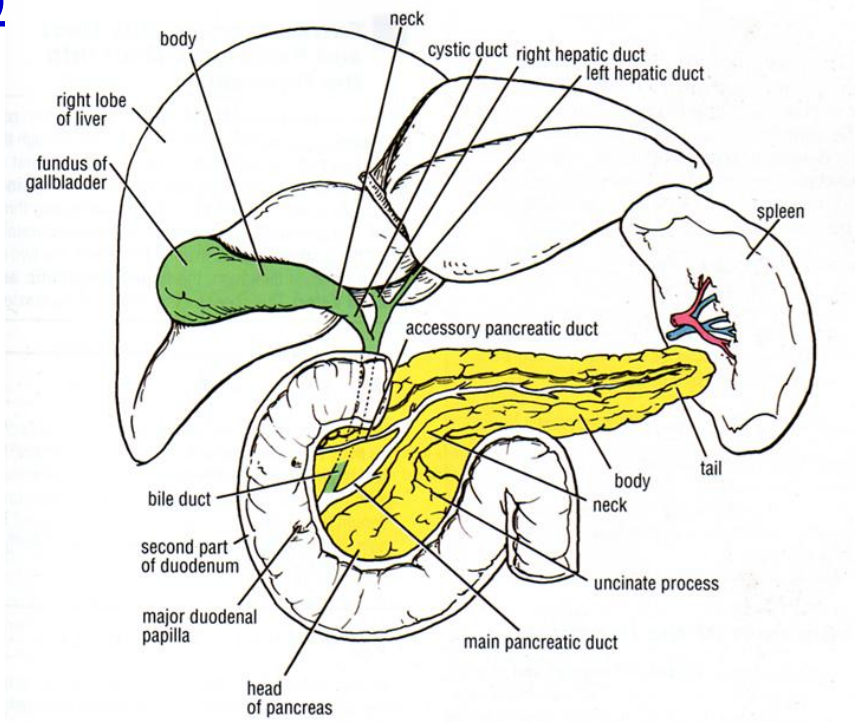

# PARTS OF DUODENUM:

## FIRST PART OF DUODENUM:

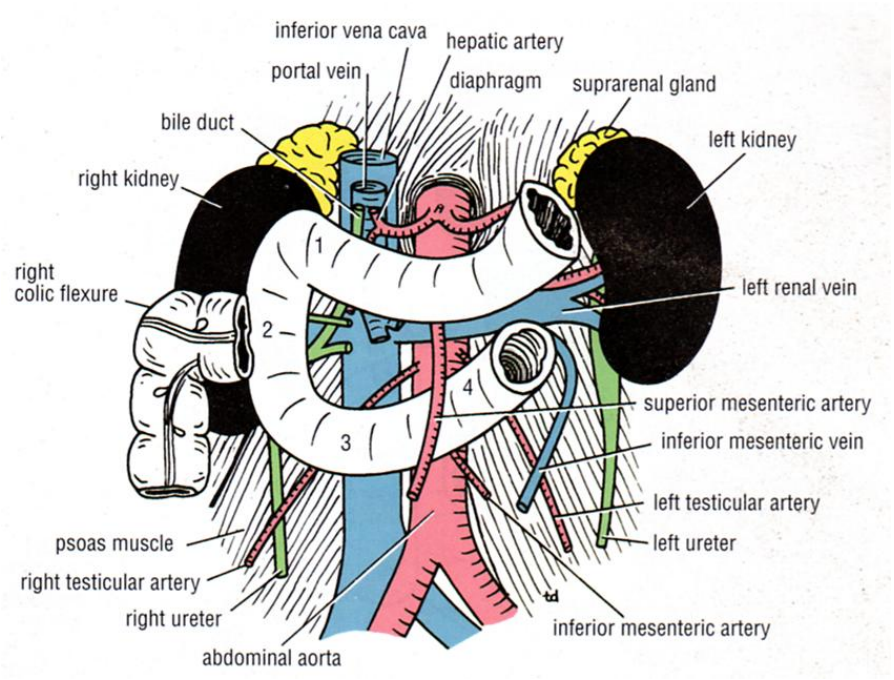


- ❖ 2 inches (5 Cm) long
- ❖ Begins at pylorus.
- ❖ Runs upward and backward at right side of 1st lumbar vertebra (transpyloric plane).

# Second Part of Duodenum

❖3 inches (7.5 Cm) long.

❖Runs vertically downward in front of hilum of right kidney on right side of 2nd and 3rd lumbar vertebrae.

❖About halfway down its medial border, bile duct and main pancreatic duct pierce duodenal wall (unite to form ampulla which opens on major duodenal papilla).

❖Accessory pancreatic duct (if present) opens into duodenum little higher up on minor duodenal papilla

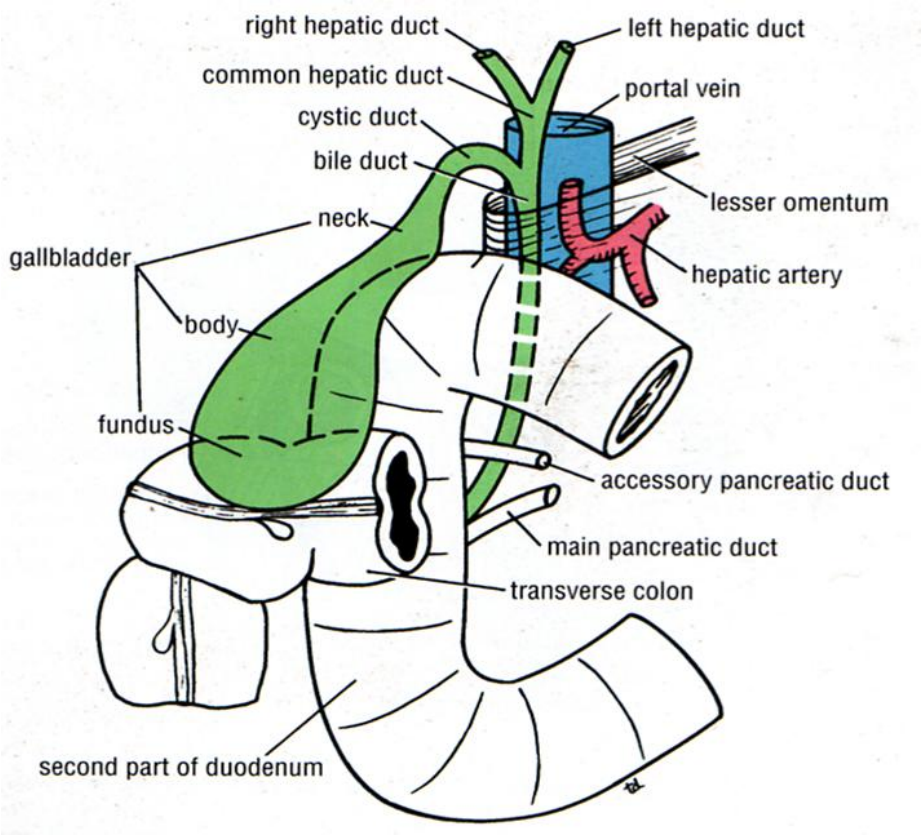

# Third Part of Duodenum

- 3 inches (7.5 Cm) long.
- Runs horizontally to left on subcostal plane.
- Passes in front of vertebral column (L 3).
- Follows lower margin of head of pancreas.

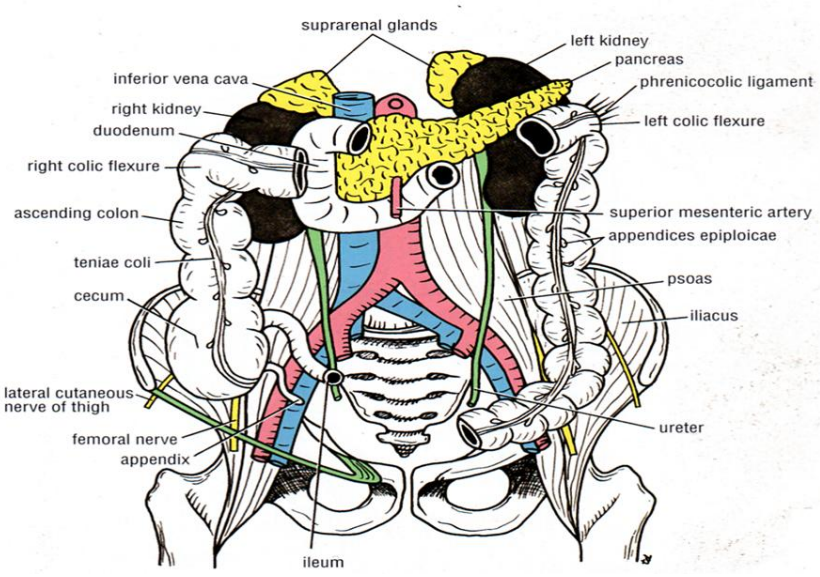

# Forth Part of Duodenum

❖2 inches (5 Cm) long.

❖Runs upward and to left to duodenojejunal flexure (left side of 2nd lumbar vertebra).

❖The flexure is held in position by ligament of Treitz, attached to right crus of diaphragm.

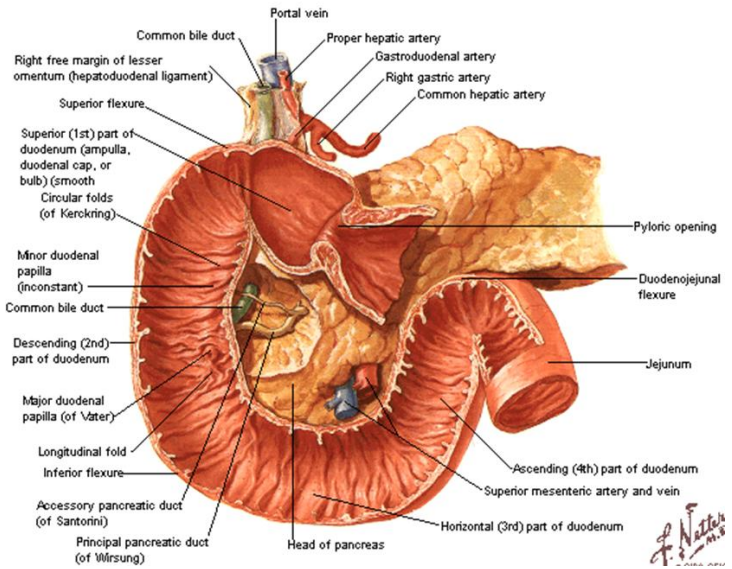


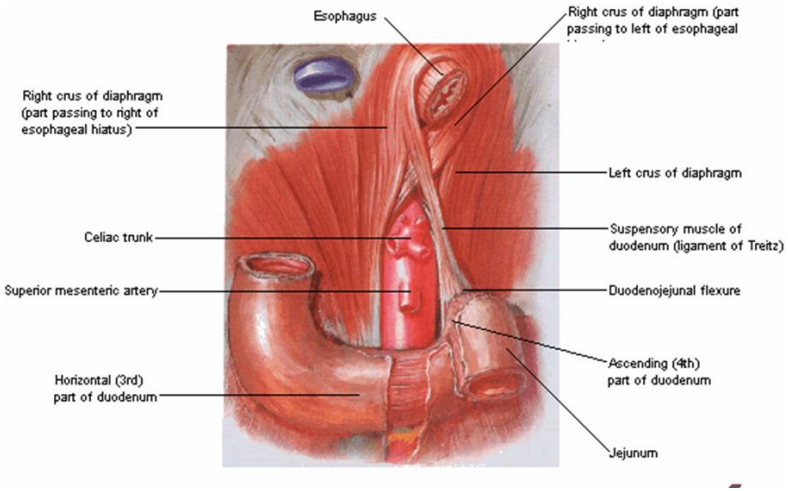

# Blood Supply of Duodenum:

- The vessels lie between concavity of duodenum and head of pancreas.

## Arteries:

### 1. Upper half of duodenum:

- Superior pancreaticoduodenal artery (gastroduodenal artery).

### 2. Lower half of duodenum:

- Inferior pancreaticoduodenal artery (superior mesenteric artery).

## Veins:

1. Superior pancreaticoduodenal vein (portal vein).
2. Inferior pancreaticoduodenal vein (superior mesenteric vein).

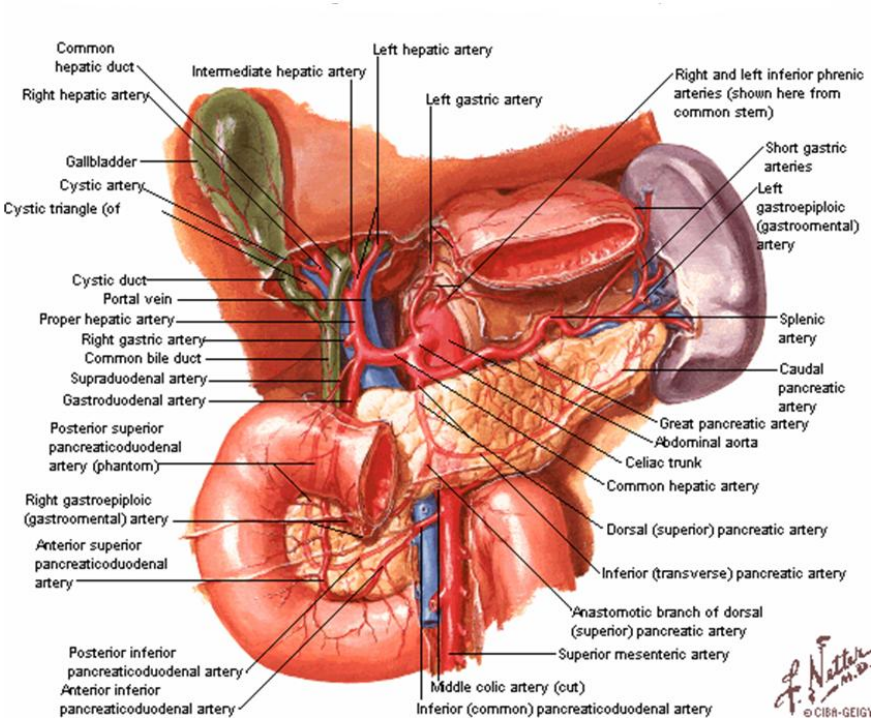

## Lymph Drainage of Duodenum

- **Follow the arteries.**
- **Drain via pancreaticouodenal nodes to gastroduodenal nodes & then to celiac nodes.**
- **Drain via pancreaticoduodenal nodes to superior mesenteric nodes.**

## Nerve Supply of Duodenum

**Derived from: Sympathetic and parasympathetic (vagus) nerves.**

**From: Celiac (foregut) and superior mesenteric (midgut) plexuses.**

# JEJUNUM AND ILEUM

## Location and Description:

- ❖Measure about 20 feet (6 m) long
- ❖Upper two-fifths being jejunum
- ❖Jejunum begins at duodenojejunal flexure
- ❖Ileum ends at ileocecal junction
- ❖Coils of jejunum and ileum are freely mobile and attached to posterior abdominal wall by *mesentery of small intestine*

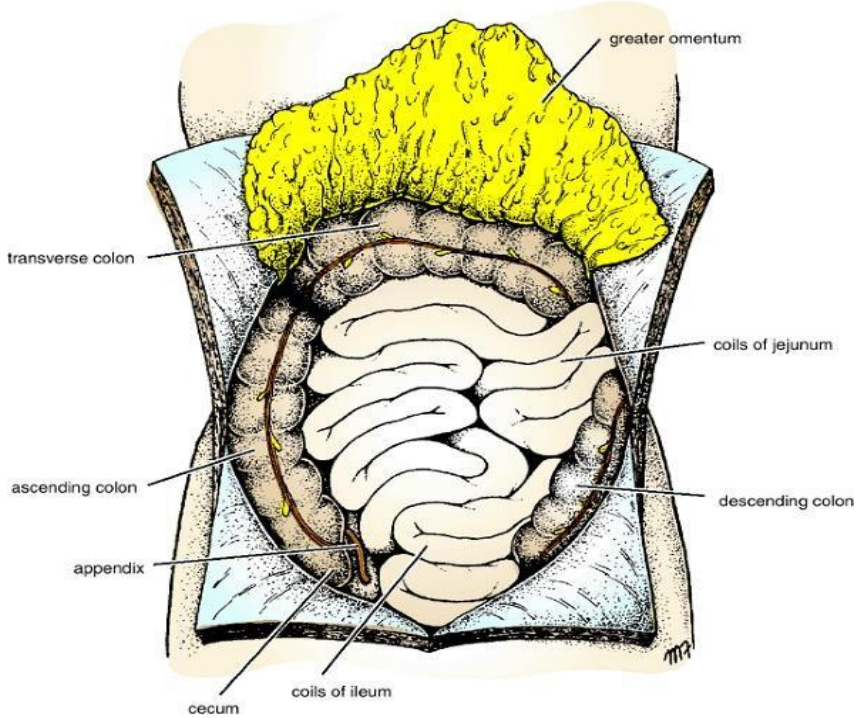


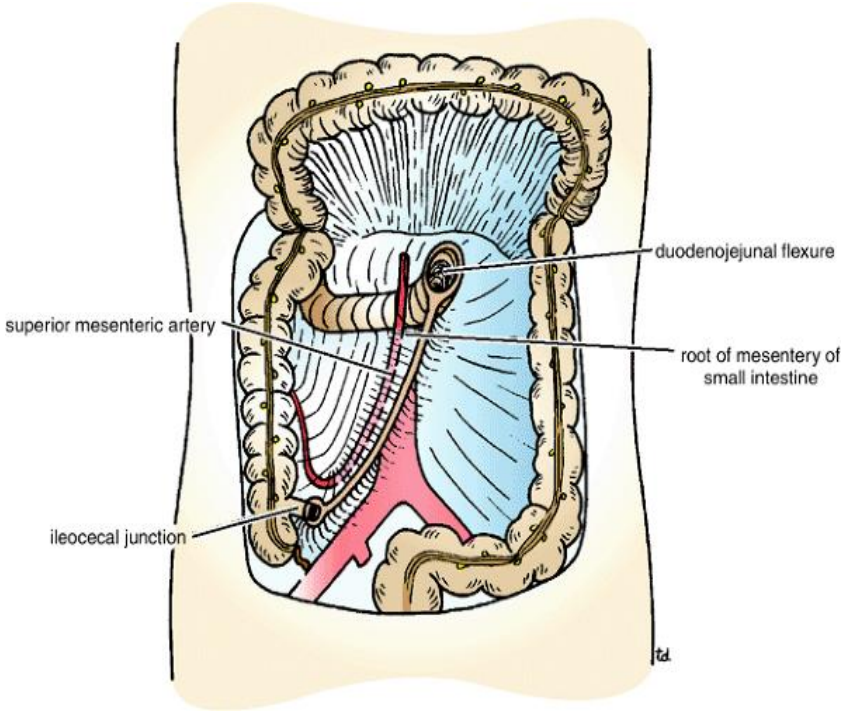

## End of Small Intestine:

❖Terminal part of ileum enters large intestine at junction of cecum with ascending colon.

❖The opening is provided by <u>ileocecal valve.</u>

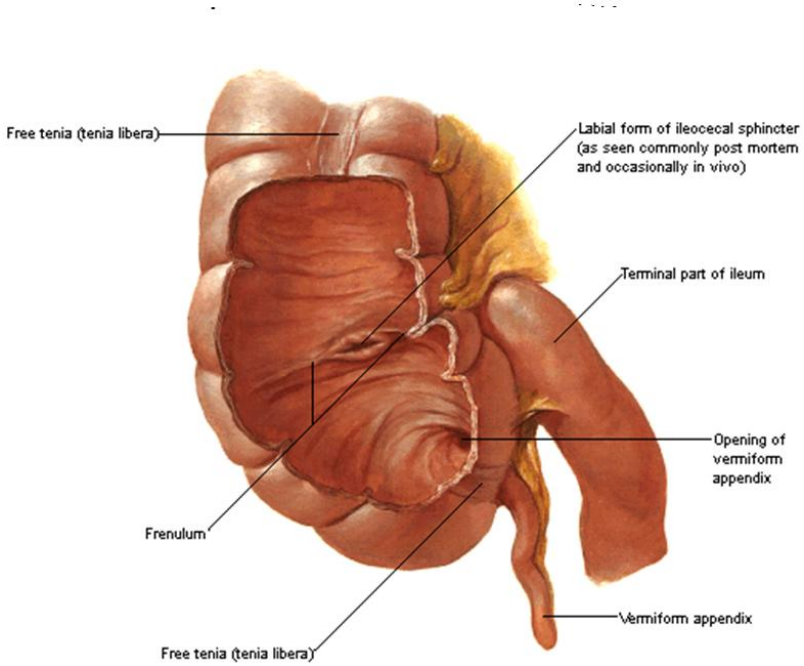


## Ileocecal valve

❖2 lips

❖Plays little or no part in prevention of reflux of cecal contents into ileum.

# MESENTRY OF SMALL INTESTINE

**Has:**

**Long free edge: Encloses mobile intestine.**

**Short root:**

- **Continuous with parietal peritoneum of posterior abdominal wall along a line extends downward and to right from left side of 2nd lumbar vertebra to right sacroiliac joint.**
- **Permits entrance and exit of branches of superior mesenteric artery and vein, lymph vessels and nerves between two layers of the mesentery.**

# Arterial Supply of Jejunum and Ilium:

## Branches of Superior mesenteric artery:-

1. Jejunal branches of superior mesenteric artery.

2. Ileal branches of superior mesenteric artery.

3. Ileocolic artery (superior mesenteric artery): Supplies lowest part of the ileum.

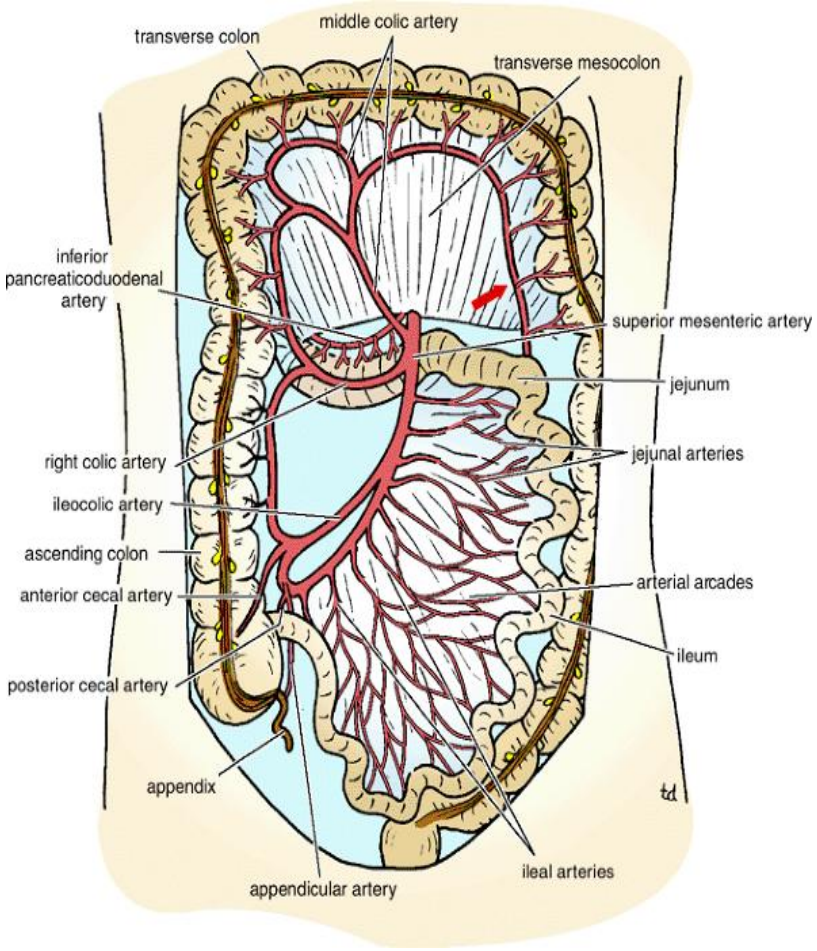

# Veinous Drainage of Jejunum and Iium:

## Tributaries of superior mesenteric vein (Portal vein):-

1. Jejunal veins
2. Ileal veins
3. Ileocolic vein

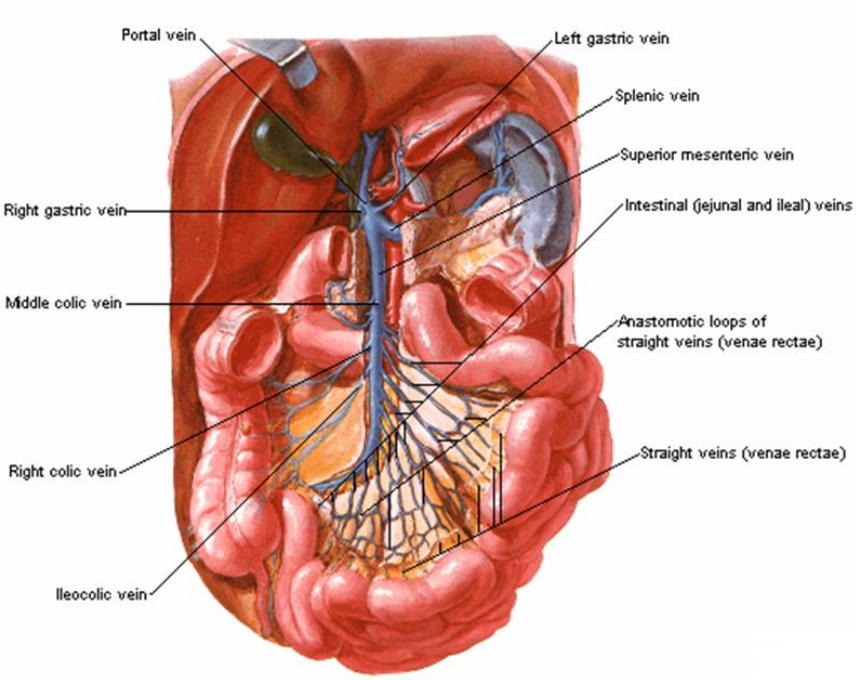


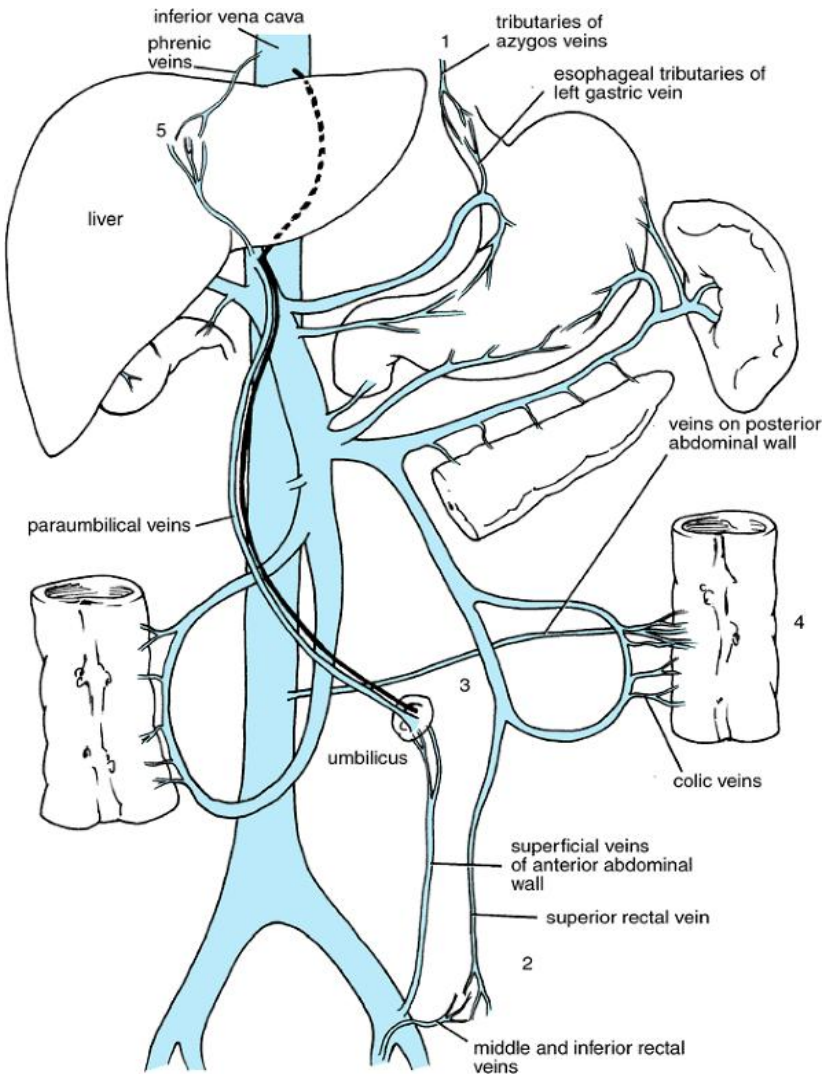

## Lymph Drainage of Jejunum and Ilium

❖ Large number of intermediate mesenteric nodes end superior mesenteric nodes (around origin of superior mesenteric artery).

## Nerve Supply of Jejunum and Ilium

❖ Sympathetic and parasympathetic (vagus) nerves from superior mesenteric plexus.

# LARGE INTESTINE

- Extends from ileum to anus.

**Divided into:**

1. Cecum
2. Appendix
3. Ascending colon
4. Transverse colon
5. Descending colon
6. Sigmoid colon
7. Rectum
8. Anal canal

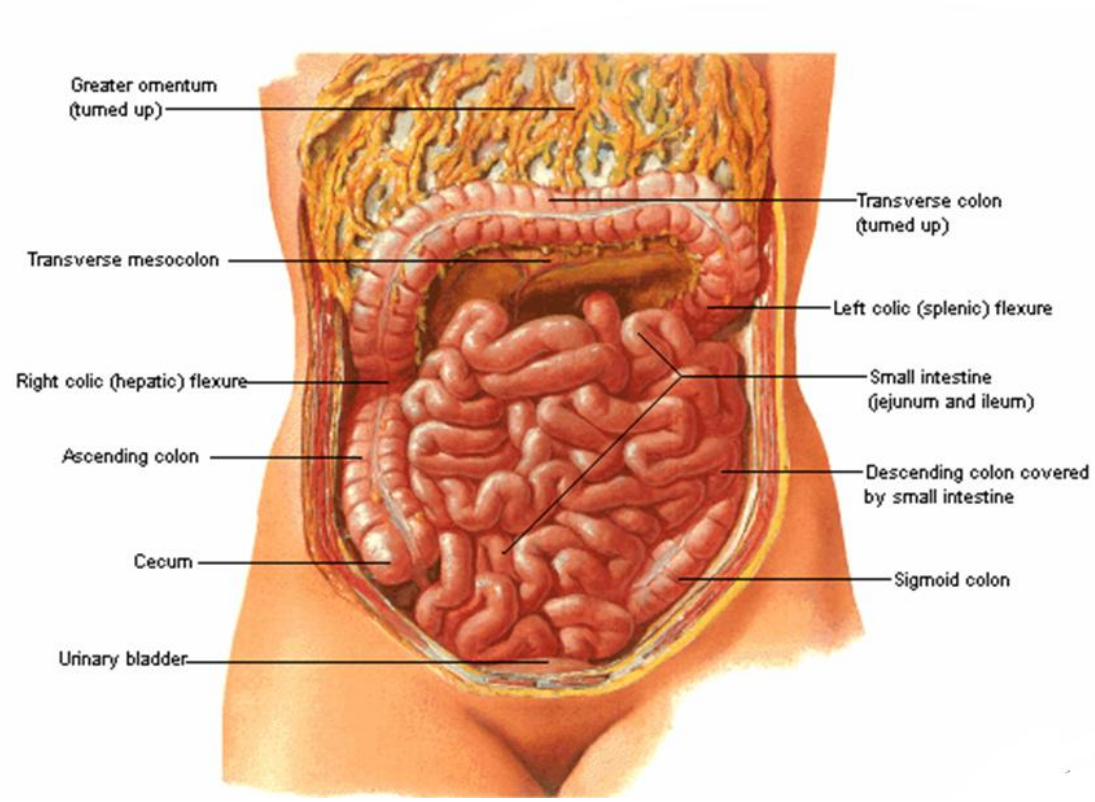

# CECUM

## Location And Description:

- Part of large intestine below level of junction of ileum with large intestine
- Blind-ended pouch situated in right iliac fossa
- About 2.5 inches (6 Cm) long
- Completely covered with peritoneum
- Possesses considerable amount of mobility, although has not a mesentery
- Appendix is attached to its posteromedial surface
- Presence of peritoneal folds creates superior ileocecal, inferior ileocecal and retrocecal fossae.

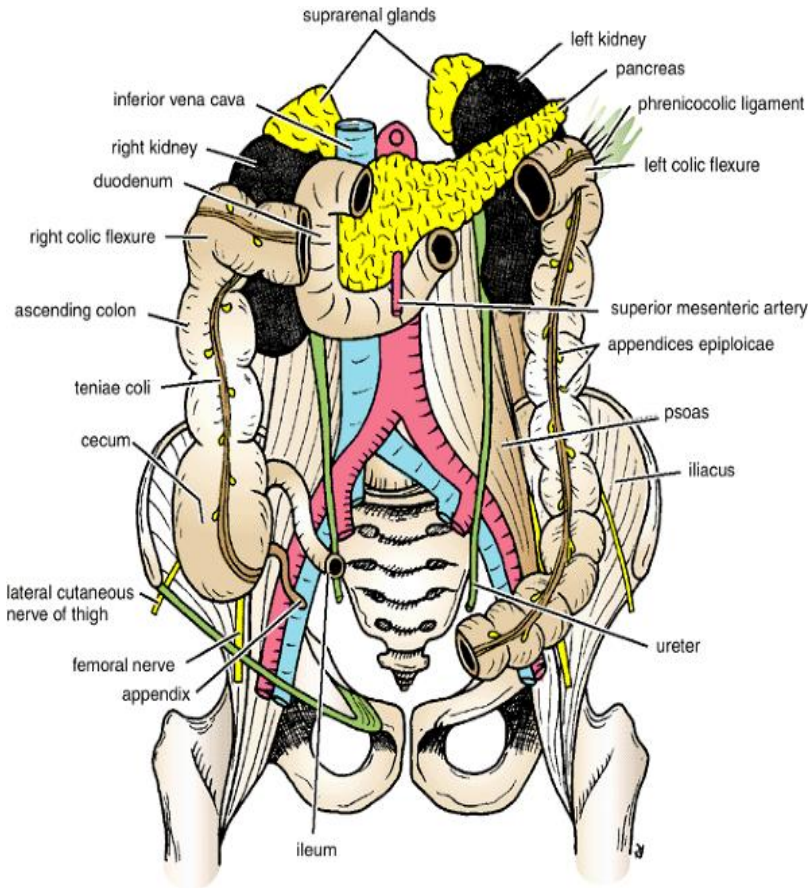


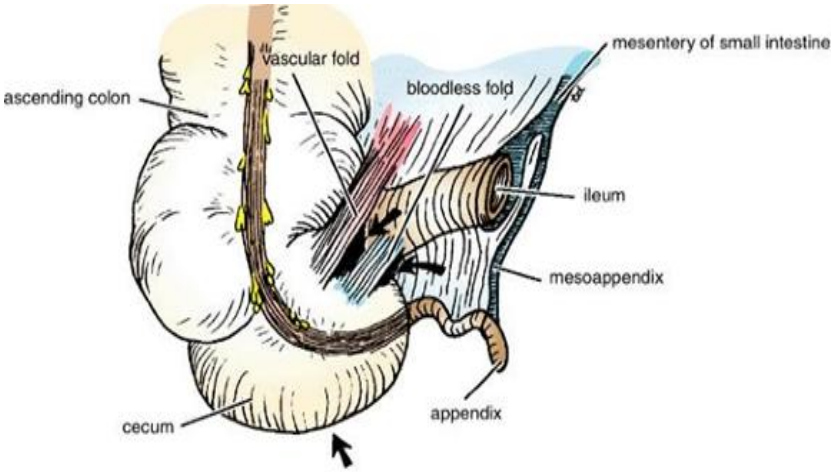

## Tineae coli:

- 3 flat bands of longitudinal muscle
- Converge on base of appendix and provide for it complete muscle coat.

**Note:**

- **Cecum:** Often distended with gas, can be palpated through anterior abdominal wall in living.

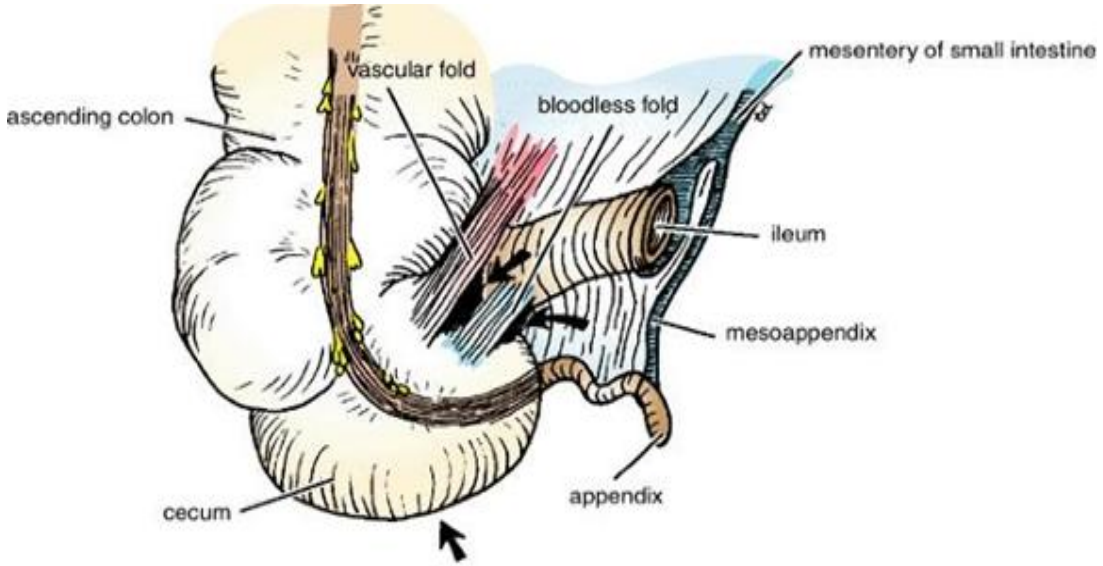

# Blood Supply of Cecum:

## Arteries: Midgut

1. Anterior cecal artery
2. Posterior cecal artery
3. Branches of ileocolic artery (superior mesenteric artery)

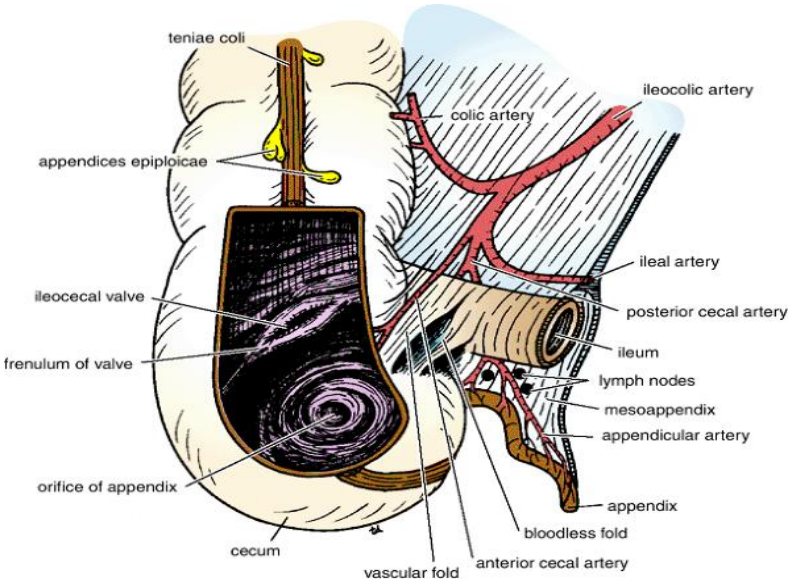


## Veins: Portal vein

1. Anterior cecal vein
2. Posterior cecal vein
3. Tributaries of ileocolic vein (superior mesenteric vein)

# APPENDIX VERMIFORMIS

- Narrow muscular tube containing large amount of lymphoid tissue

**Length**: 3 to 5 inches (8-13 Cm).

**Base**: Attached to posteromedial surface of cecum about 1 inch below ileocecal junction.

**Remainder of appendix**:

- Free has complete peritoneal covering.
- Attached to lower layer of mesentery of small intestine by mesoappendix (contains appendicular vessels and nerves).

**Site**: Right iliac fossa in relation to anterior abdominal wall.

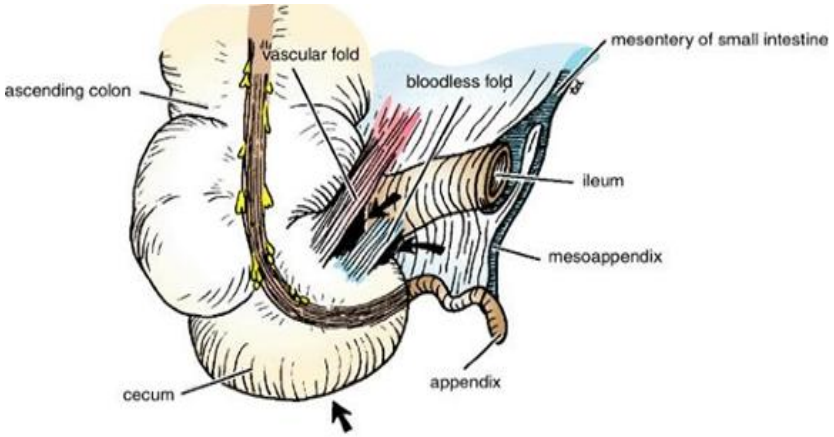

## Lymph Drainage of Cecum:

- Superior mesenteric lymph nodes.

## Nerve Supply of Cecum:

- Sympathetic and parasympathetic (vagus) nerves from superior mesenteric plexus.

## Blood Supply of Appendix Vermiformis:

**Arteries: Superior mesenteric artery**
**Appendicular artery: Branch of posterior cecal artery, passes up to tip of appendix in mesoappendix.**
**Veins: Portal vein, Appendicular vein: Joins posterior cecal vein.**

## Lymph Drainage of Appendix Vermiformis:

- **Drain to one or two lymph nodes in mesoappendix, end in superior mesenteric lymph nodes.**

## Nerve Supply of Appendix Vermiformis:

- **Sympathetic and parasympathetic (vagus) nerves from superior mesenteric plexus.**
- **Afferent nerve fibres of visceral pain accompany sympathetic nerves and enter spinal cord at level of 10th thoracic segment.**

## Surface anatomy of of base of appendix:

### McBurney's point:

- Point at junction of lateral 1/3 and middle 1/3 of line extending from right anterior superior iliac spine to the umbilicus.

## Common sites of tip of appendix:

- Behind cecum in retrocecal fossa; *retrocecal*
- Into pelvis against right pelvic wall; *pelvic*
- Along lateral side of cecum
- Front terminal part of ileum; *preileal*
- Behind terminal part of ileum; *postileal*

- Retrocecal and pelvic are most common sites

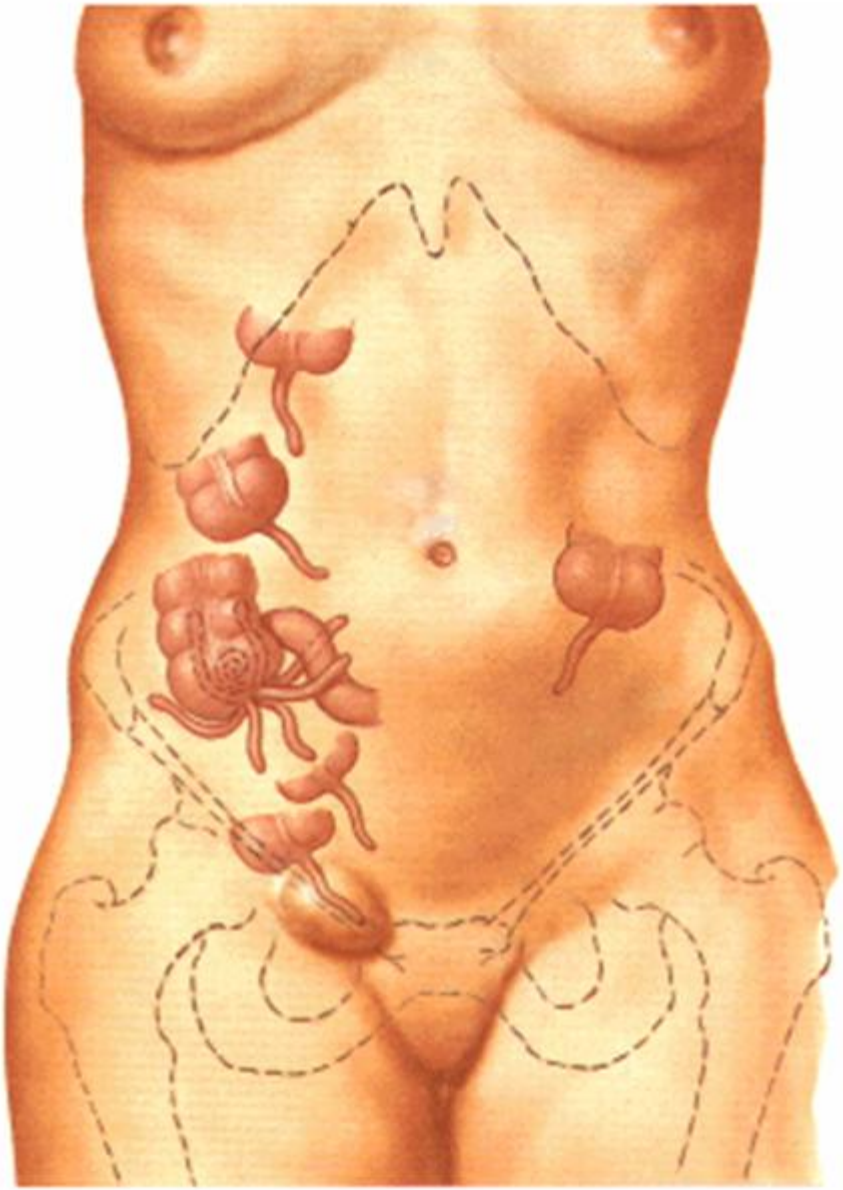

# ASCENDING COLON

**About 5 inches (13 Cm) long**

**Site: Right lower quadrant**

**Extends:**

- **Upward from the cecum to inferior surface of right lobe of the liver, where turns to the left forming right colic flexure and become continuous with transverse colon.**
- **Peritoneum covers front and sides of ascending colon binding it to posterior abdominal wall.**

# Blood Supply of Ascending Colon

## Arteries:

**Branches of superior mesenteric artery**

1. Ileocolic artery
2. Right colic artery

## Veins:

**Tributaries of superior mesenteric vein (Portal vein)**

1. Ileocolic vein
2. Right colic vein

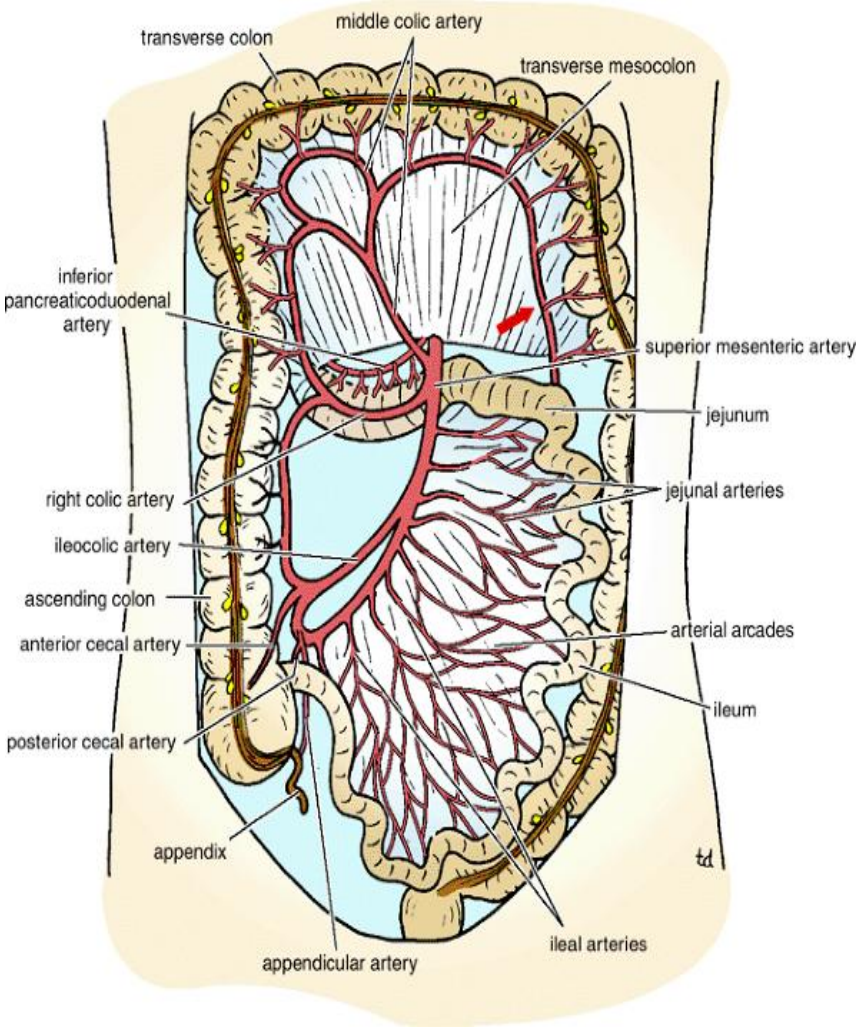

## Lymph Drainage of Ascending Colon:

- **Lymph nodes along course of colic blood vessels end in superior mesenteric lymph nodes.**

## Nerve Supply of Ascending Colon:

- **Sympathetic and parasympathetic (vagus) branches from superior mesenteric plexus.**

# TRANSVERSE COLON

- About 15 inches (38 Cm) long
- Extends across the abdomen occupying umbilical region.

**Begins:**

- At right colic flexure below right lobe of liver.

**Suspended by:**

- Transverse mesocolon.

**Ends:**

- At left colic flexure below spleen.

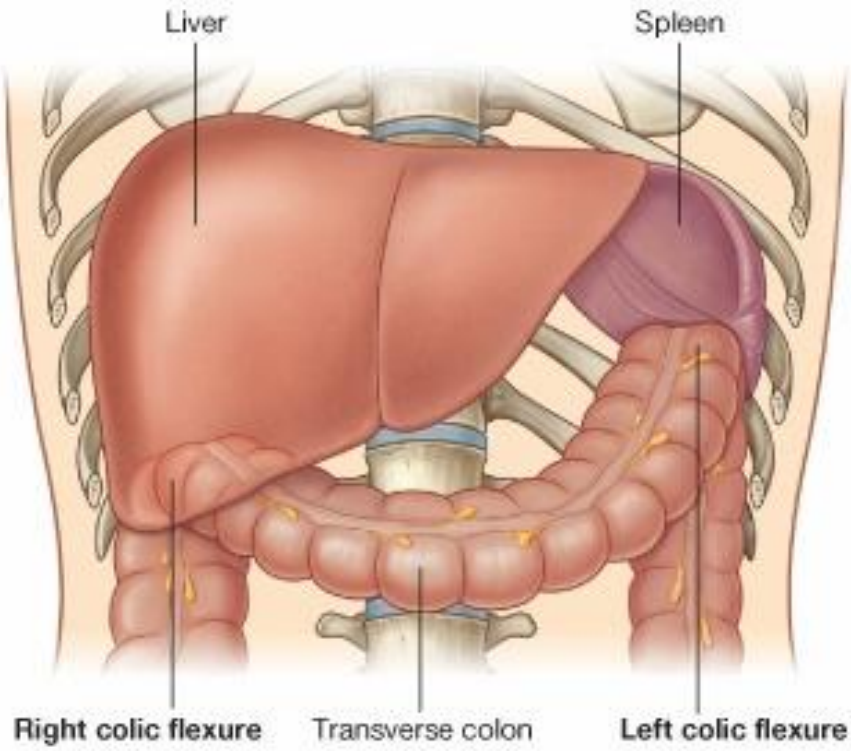

## Left colic flexure:

- Higher than right colic flexure and suspended from diaphragm by phrenicocolic ligament.

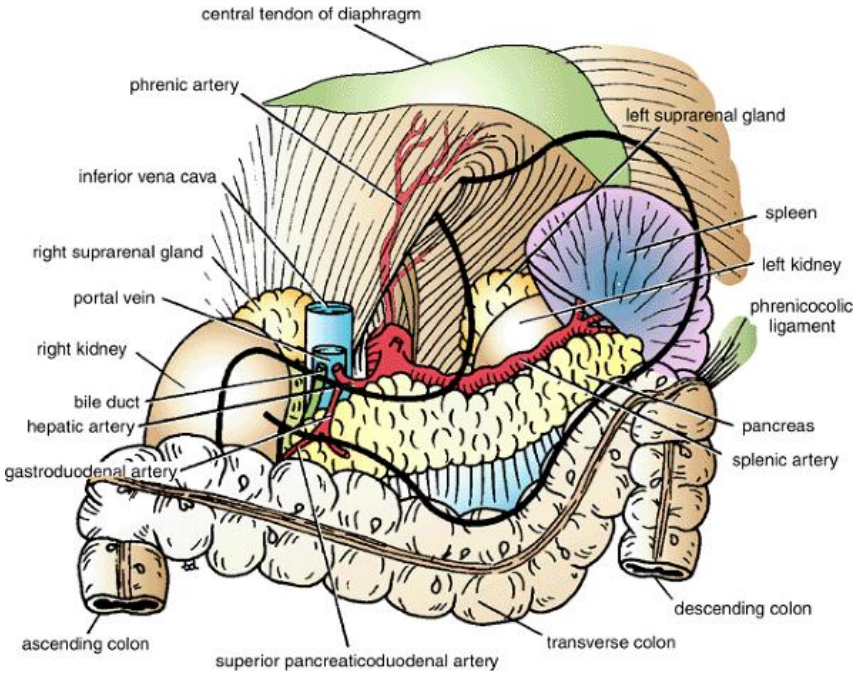


## Transverse mesocolon:

## Suspends:

- Transverse colon from anterior border of pancreas.

## Attached to:

- Sup border of transverse colon.
- Posterior layers of greater omentum attached to the inferior border.

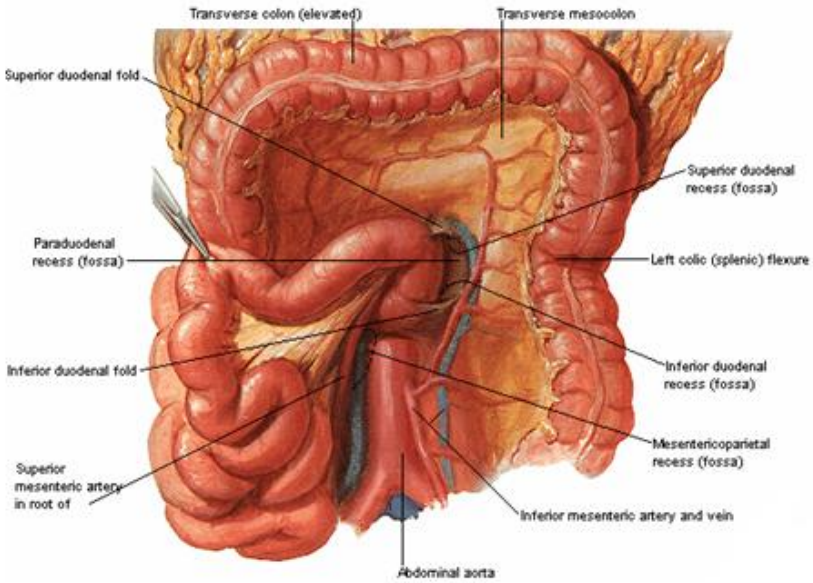

# Blood Supply of Transverse Colon:

## Arteries:

**Right 2/3: Midgut, Middle colic artery (superior mesenteric artery).**

**Left 1/3: Hindgut, Left colic artery (inferior mesenteric artery).**

## Veins: Portal vein

**Right 2/3: Middle colic vein (superior mesenteric vein).**

**Left 1/3: Left colic vein (inferior mesenteric vein).**

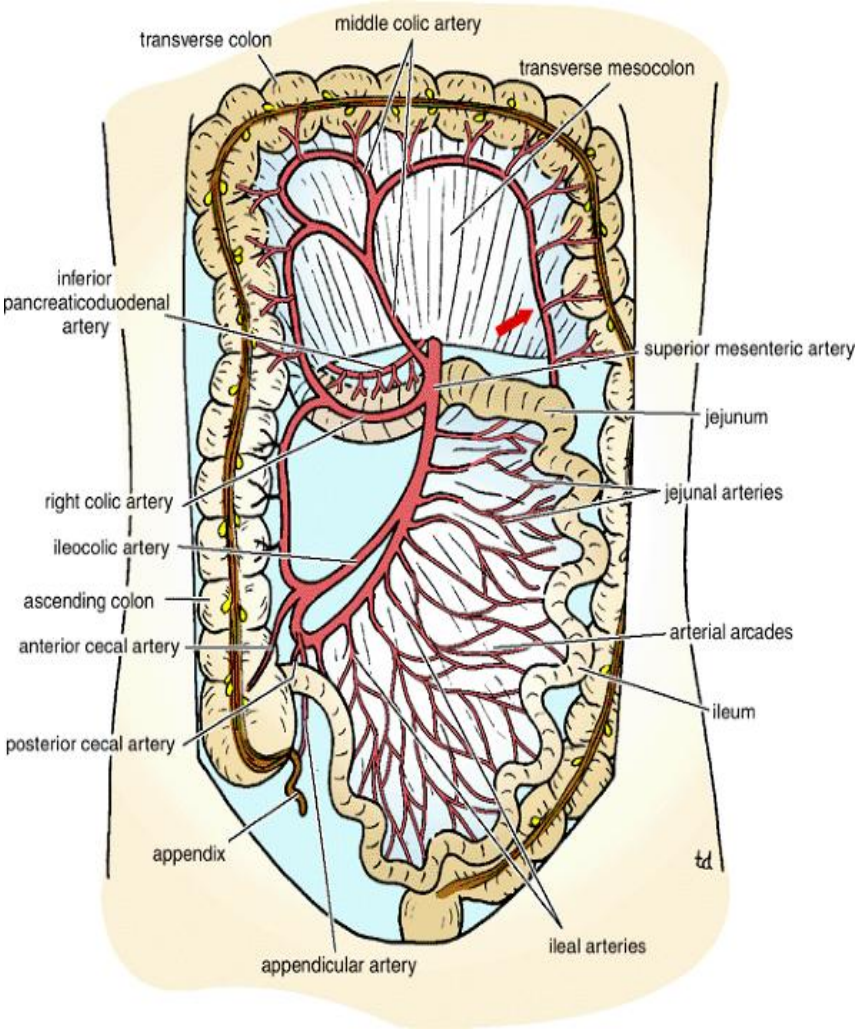

**Lymph Drainage of Transverse Colon:**

- **Lymph nodes along colic vessels**

**Right 2/3: Superior mesenteric nodes.**

**Left 1/3: Inferior mesenteric nodes.**

**Nerve Supply of Transverse Colon:**

**Right 2/3:**

**Sympathetic and vagus nerves through superior mesenteric plexus.**

**Left 1/3:**

**Sympathetic and parasympathetic pelvic splanchnic nerves through inferior mesenteric plexus.**

# DESCENDING COLON

- About 10 inches (25 Cm) long

**Site**: Left upper and lower quadrants.

**Begins**: Left colic flexure.

**Ends**:
At pelvic brim, become continuous as sigmoid colon.

**Note**: *Peritoneum covers front and sides fixes it to posterior abdominal wall.*

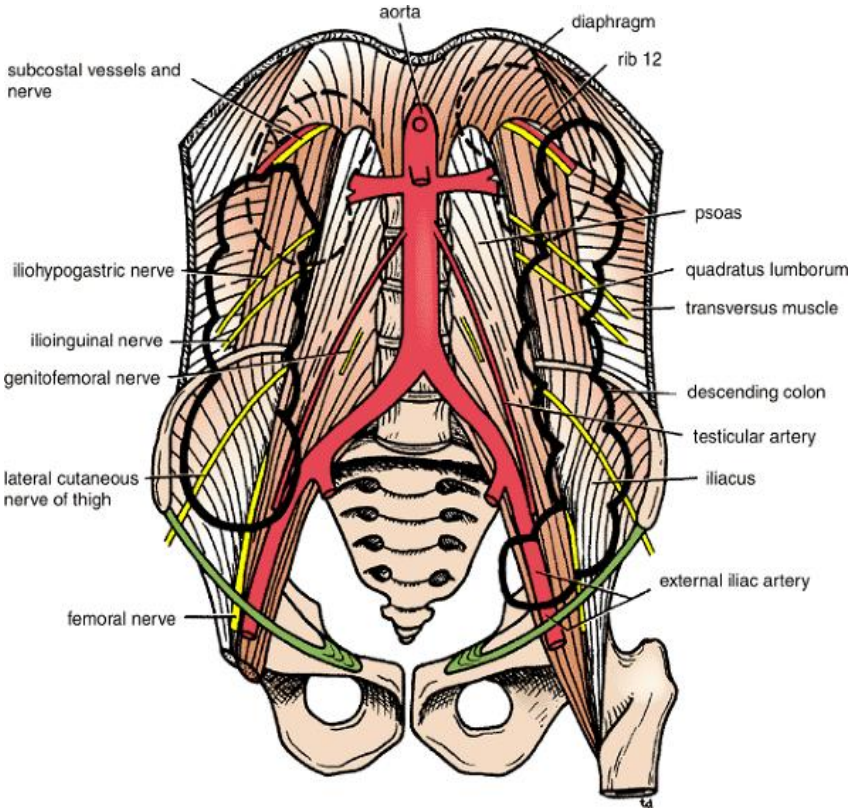

# Blood Supply of Descending Colon

**Arteries:**

**Inferior mesenteric artery**

1. Left colic artery
2. Sigmoid branches

**Veins:**

**Inferior mesenteric vein; portal vein.**

1. Left colic vein
2. Sigmoid veins

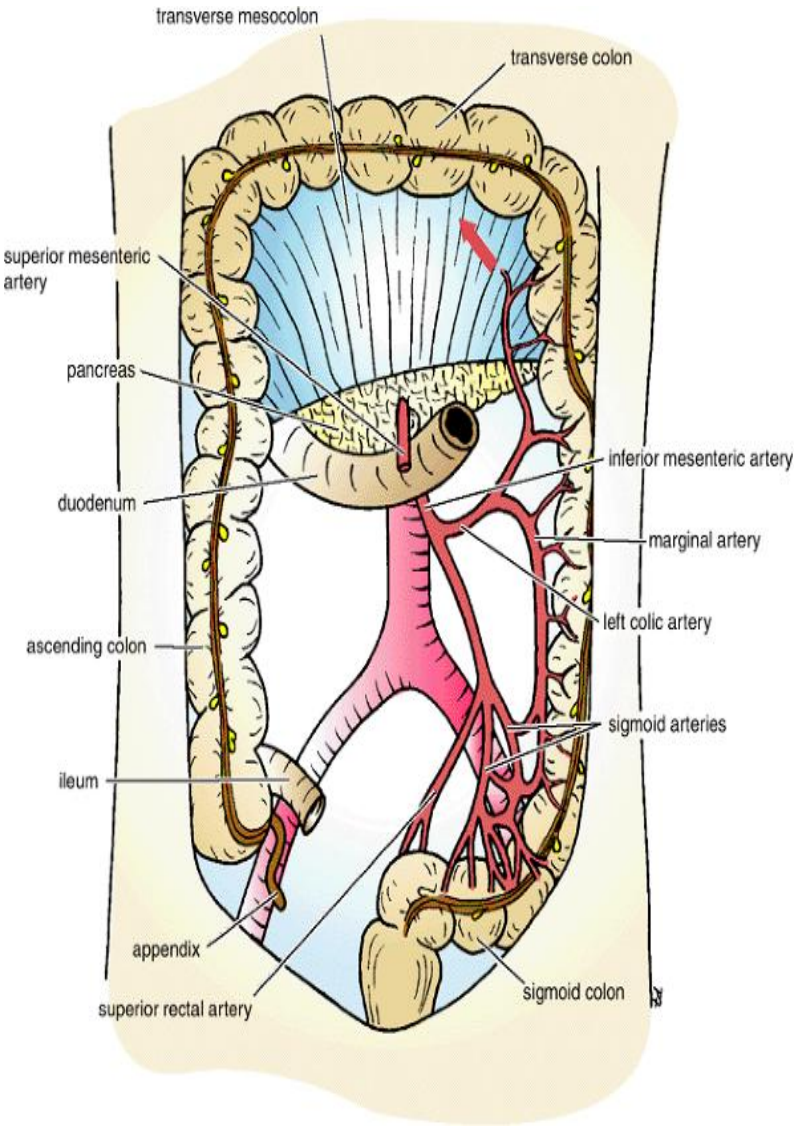

## Lymph Drainage of Descending Colon

- Lymph nodes along colic blood vessels.
- End into inferior mesenteric lymph nodes.

## Nerve Supply of Descending Colon:

- Derived from sympathetic and parasympathetic pelvic splanchnic nerves (S2, 3,4) through inferior mesenteric plexus.

# SIGMOID COLON

- 10-15 inches (25-38cm) long.

**Beginning:**

Continuation of descending colon in front of pelvic brim.

**End:**

Continues as rectum front third sacral vertebra

-Mobile, hangs into pelvic cavity in form of a loop.

-Attached to posterior pelvic wall by sigmoid mesocolon.

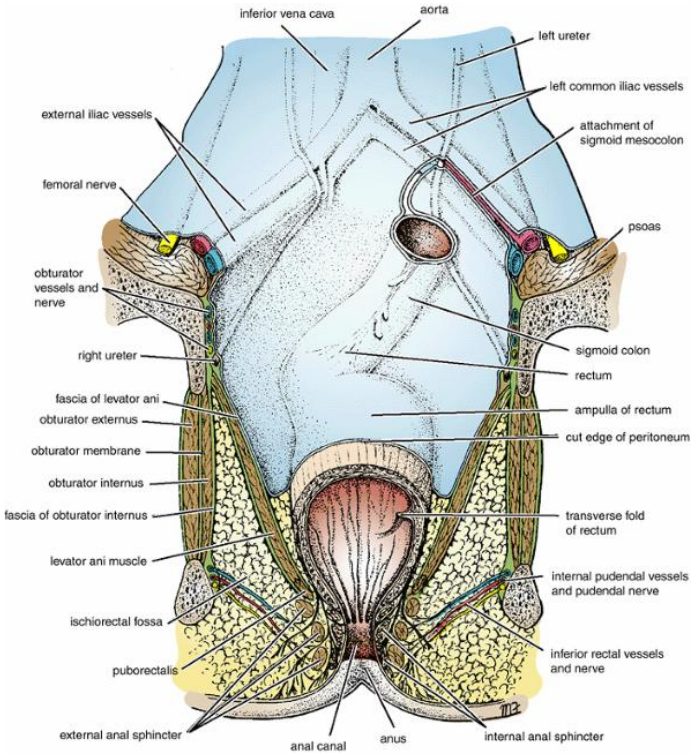


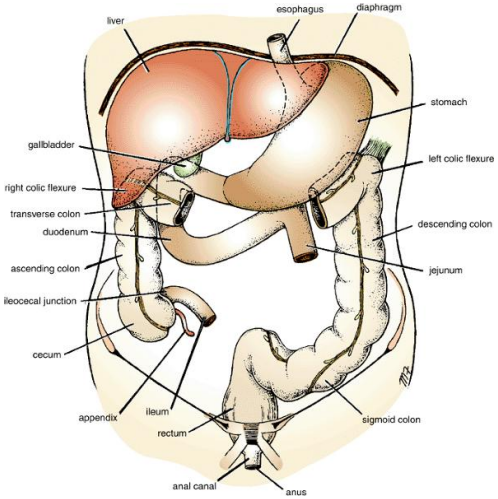


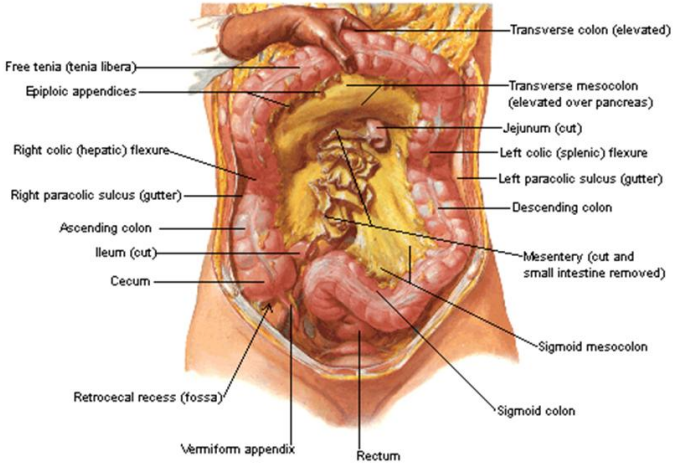

# Arterial Supply of Sigmoid Colon:

- **Sigmoid branches of inferior mesenteric artery.**

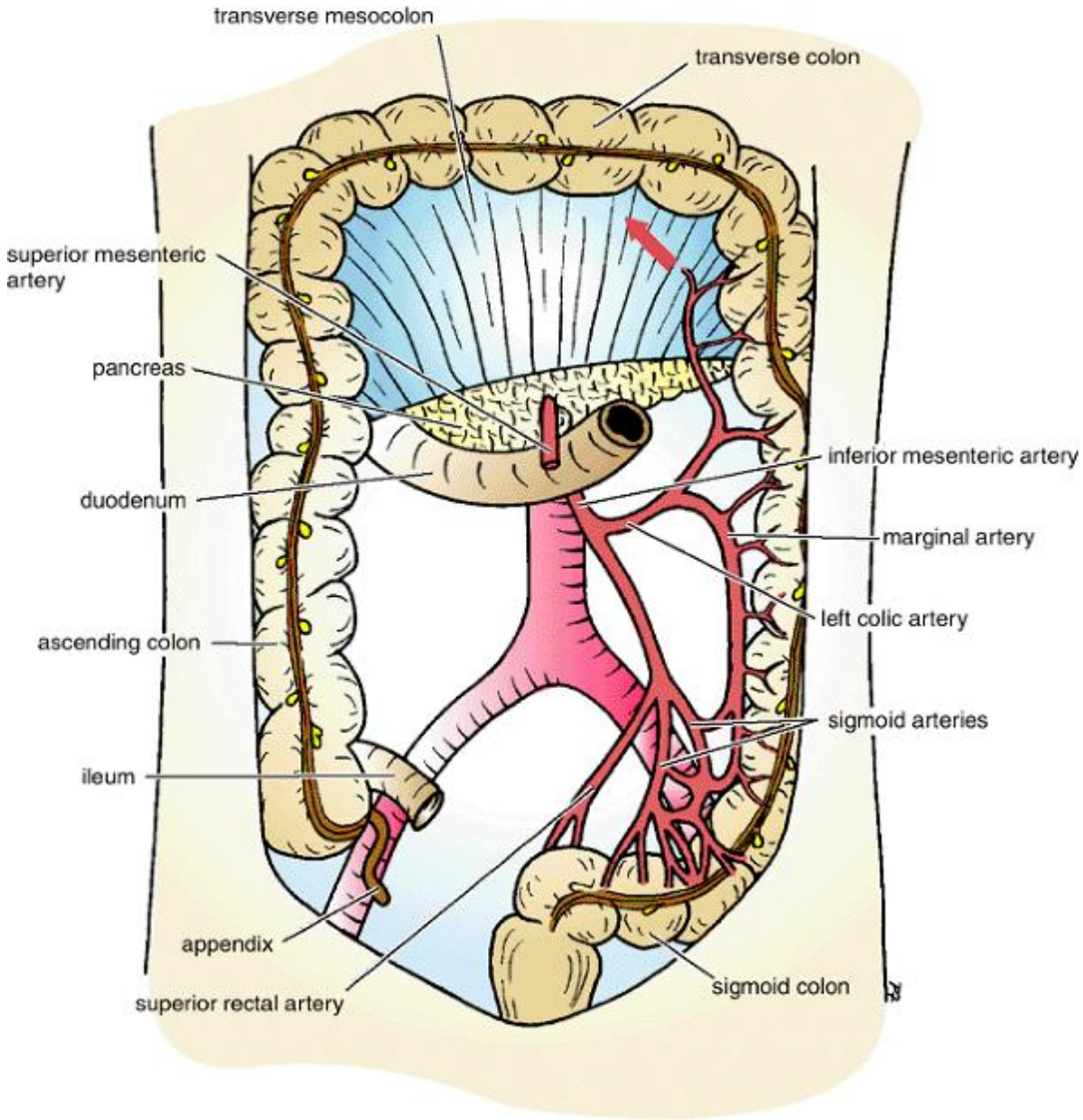

# Venous Drainage of Sigmoid Colon:

## Sigmoid veins

- Inferior mesenteric vein
- Splenic vein
- Portal vein

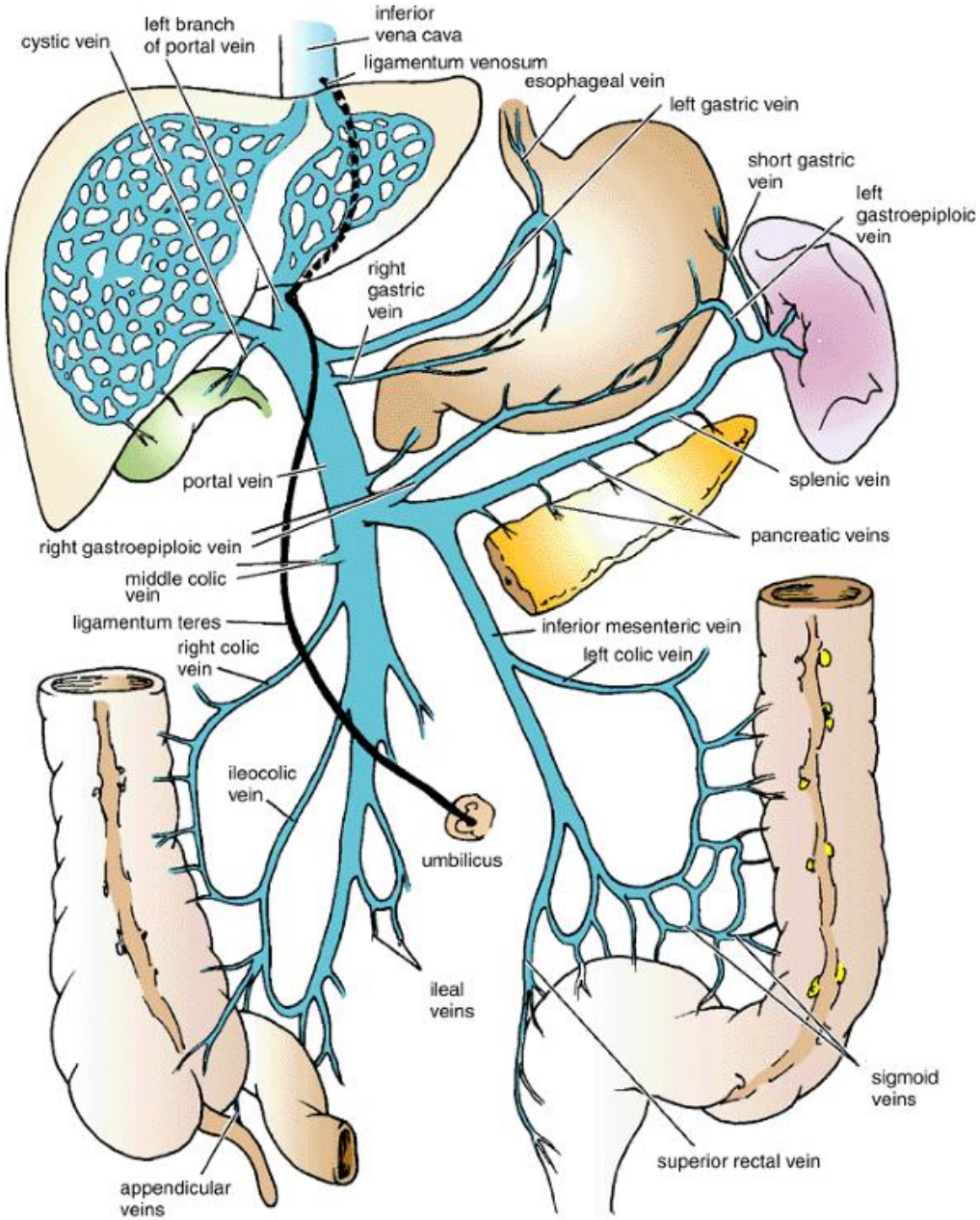

## Lymphatic Drainage of Sigmoid Colon:

- Nodes along sigmoid arteries
- Inferior mesenteric nodes.

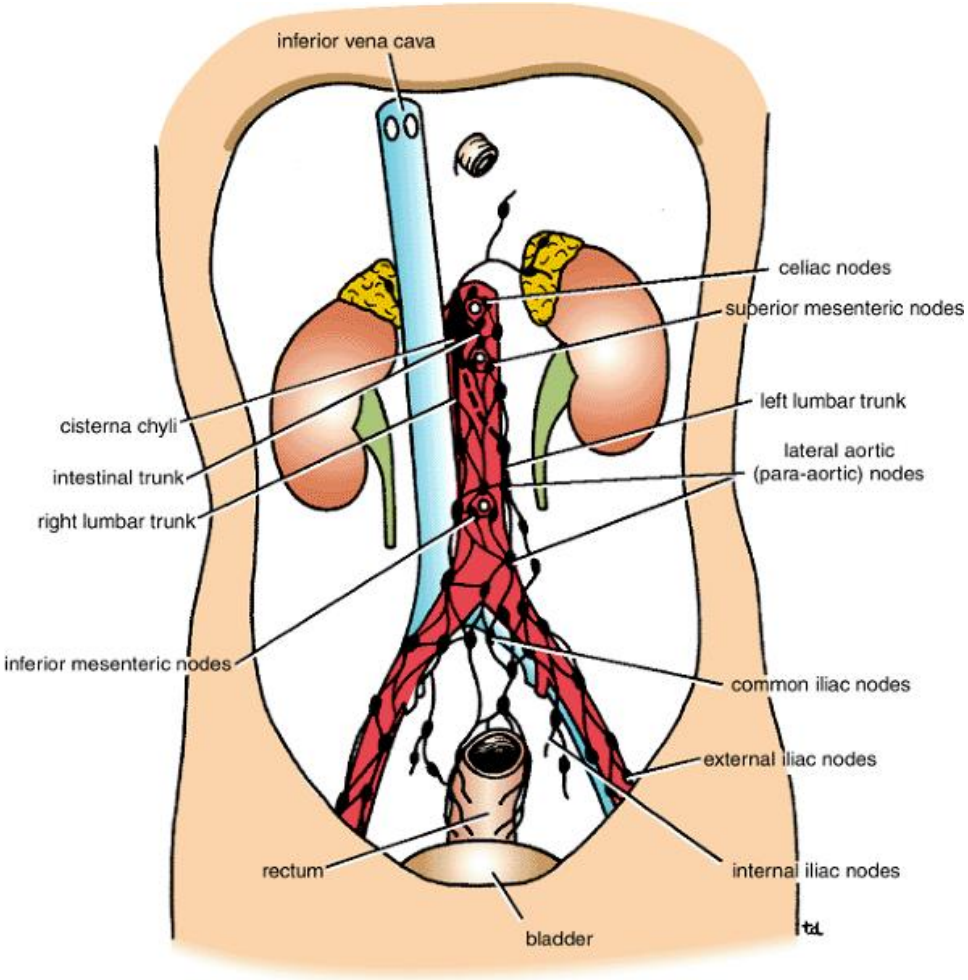

# Nerve Supply of Sigmoid Colon:

- **Sympathetic and parasympathetic nerves from inferior hypogastric plexus.**

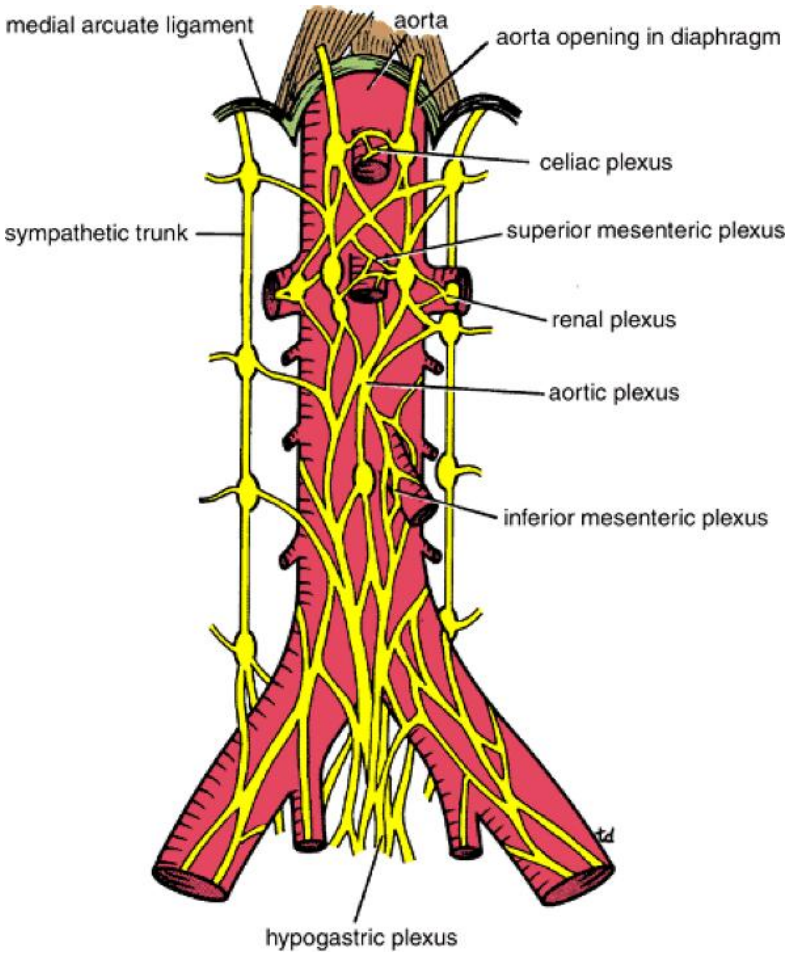


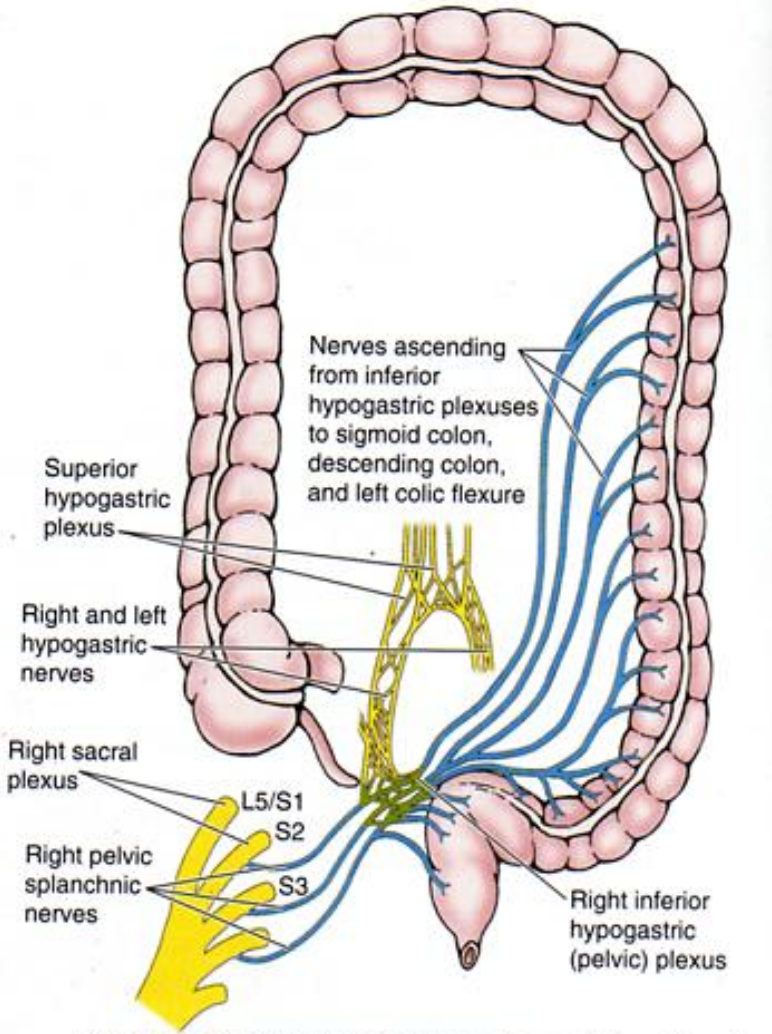


Parasympathetic nerves to descending and sigmoid colon

# RECTUM

- About 5 inches (13cm) long.

- **Beginning:**
- Continuation of sigmoid colon in front of 3rd sacral vertebra.

- **End:**
- 1 inch in front tip of coccyx continuous with anal canal.
- Lower part of the rectum dilates to form rectal ampulla.

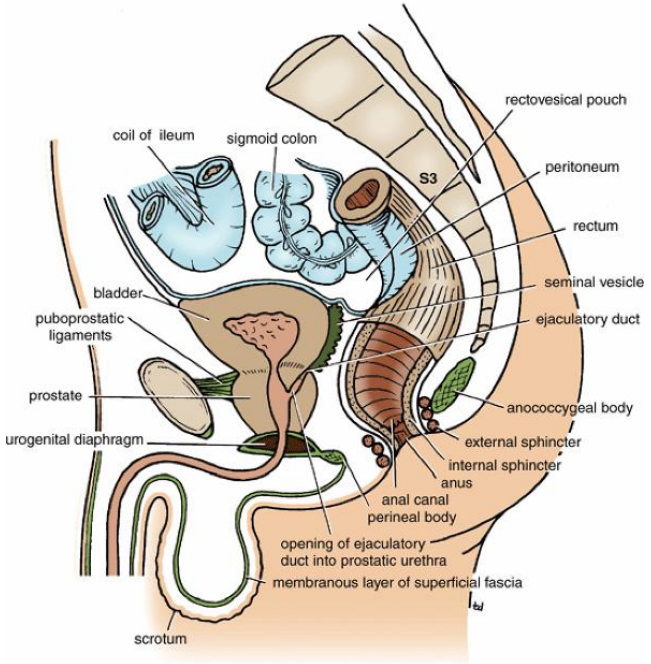


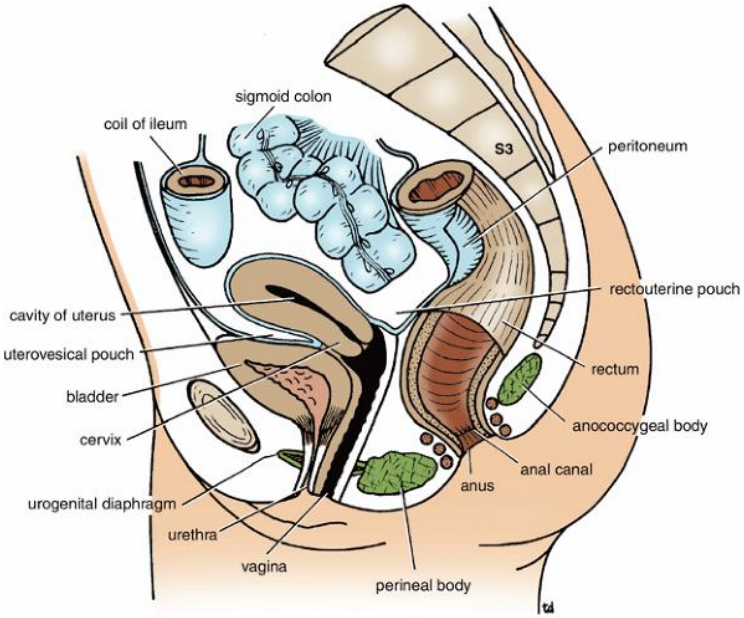

# Peritoneal Covering of the Rectum;

- **Upper 1/3: Anterior and lateral surfaces**
- **Middle 1/3: Only anterior surface**
- **Lower 1/3: No peritoneal covering**

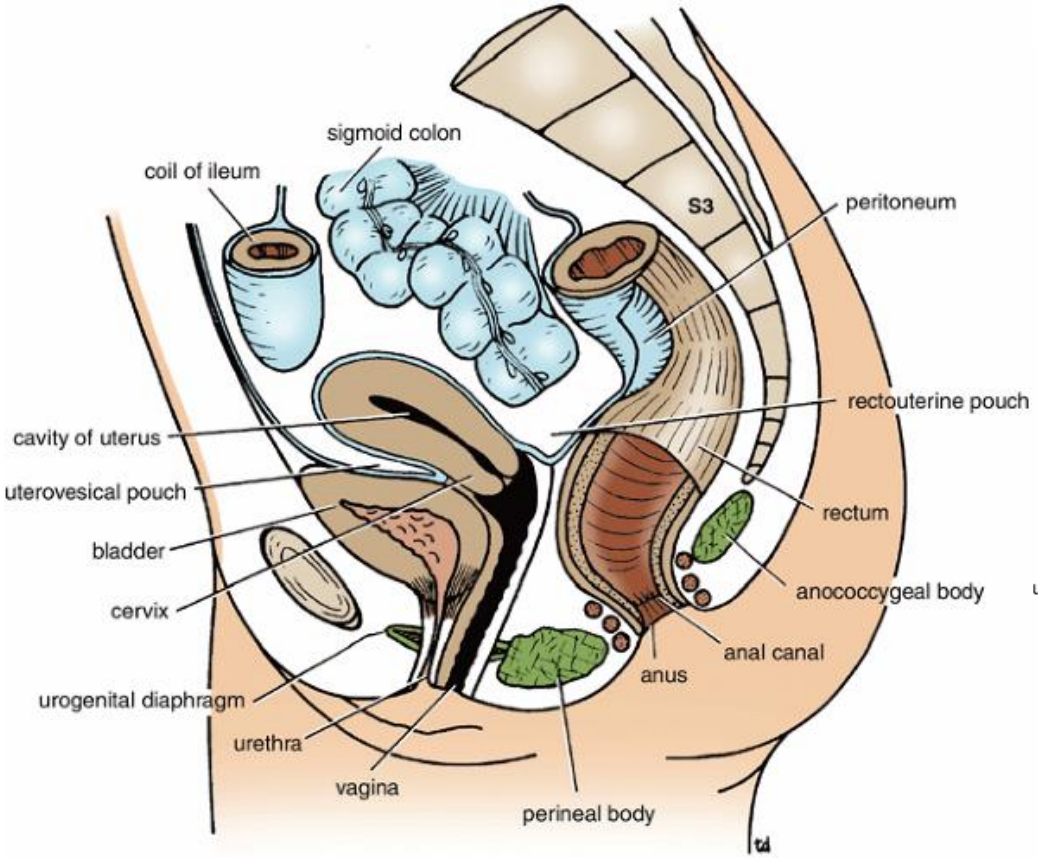


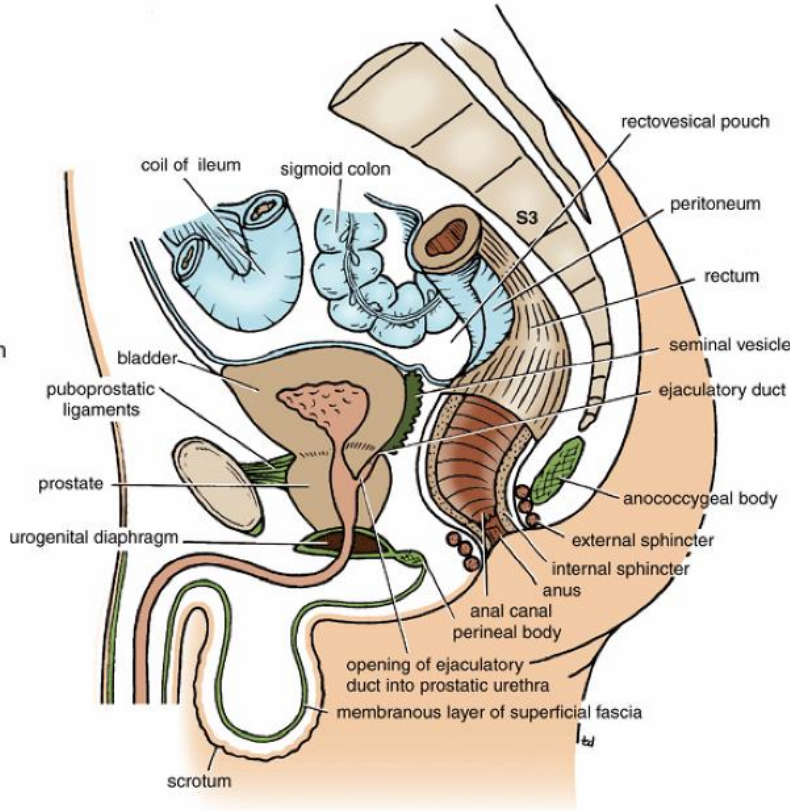

•**Muscular Coat of Rectum:** Arranged into outer longitudinal, inner circular layers of smooth muscles.

•**3 teniae coli of Sigmoid Colon:** Come together to form broad band on anterior and posterior surfaces of rectum.

•**Mucous membrane together with circular muscle layers form:** 3 permanent folds; ***transverse folds of rectum***; semicircular, 2 placed on left rectal wall and the middle on the right.

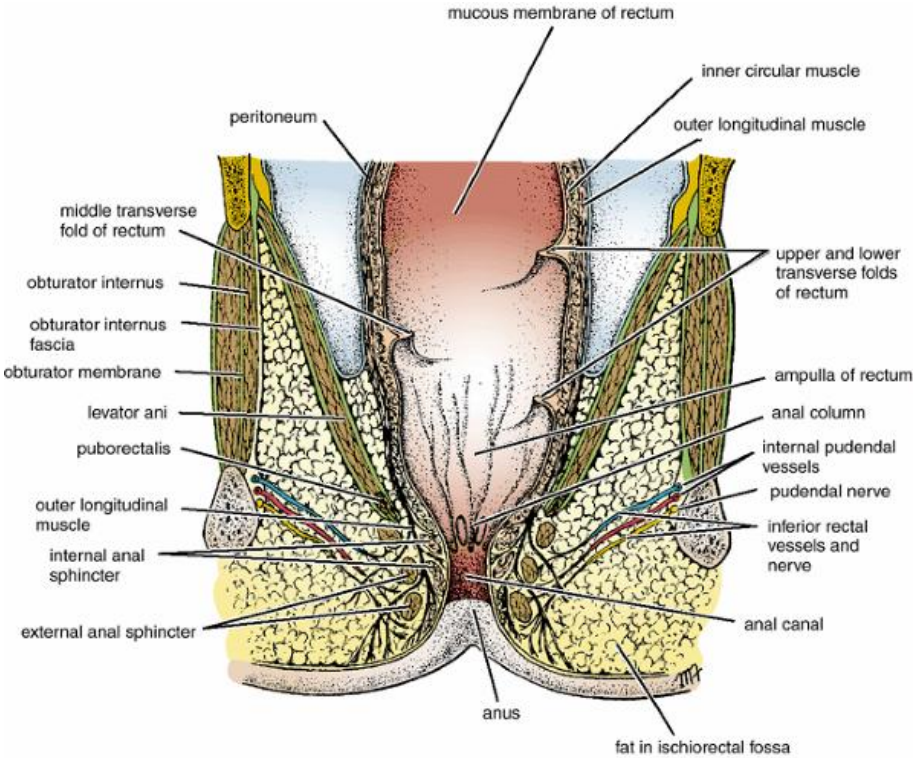

## Arterial Supply of Rectum:

1. Superior rectal artery (continuation of inferior mesenteric artery).

2. Middle rectal artery (branch of internal iliac artery).

3. Inferior rectal artery (branch of internal pudendal artery)

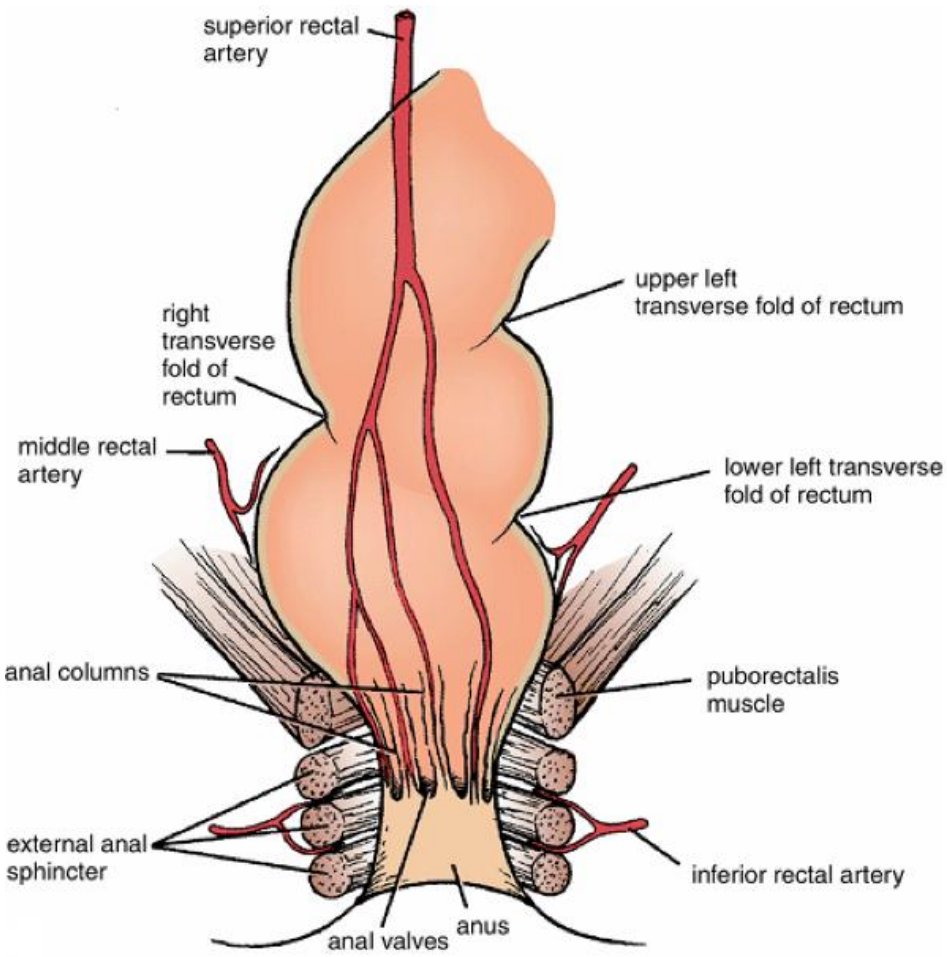

# Venous Drainage of Rectum:

1. **Superior rectal vein: Branch of inferior mesenteric vein, drains into splenic vein (portal vein).**

2. **Middle rectal vein: Branch of internal iliac vein (systemic circulation).**

3. **Inferior rectal vein: Branch of internal pudendal vein (systemic circulation).**

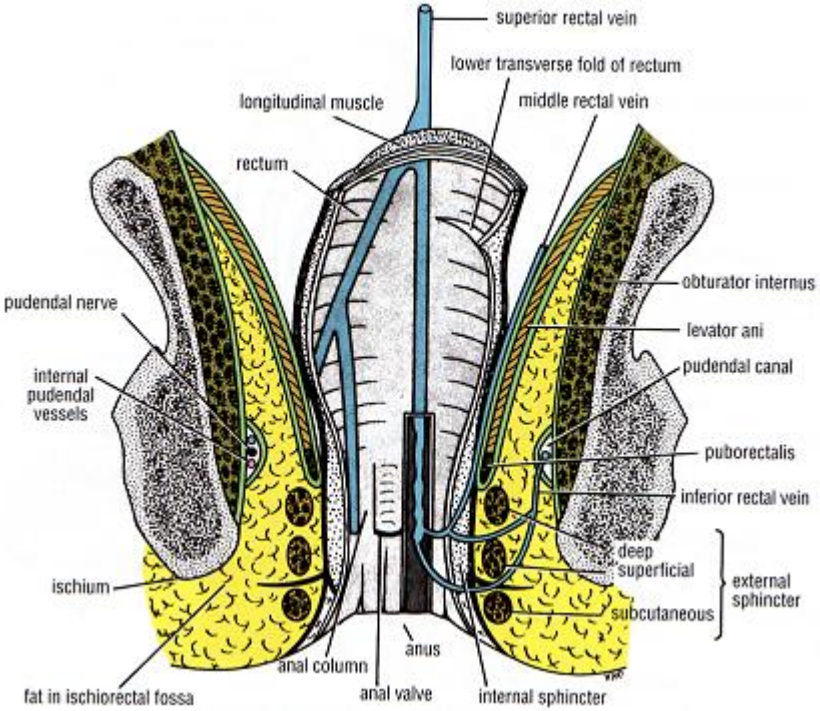


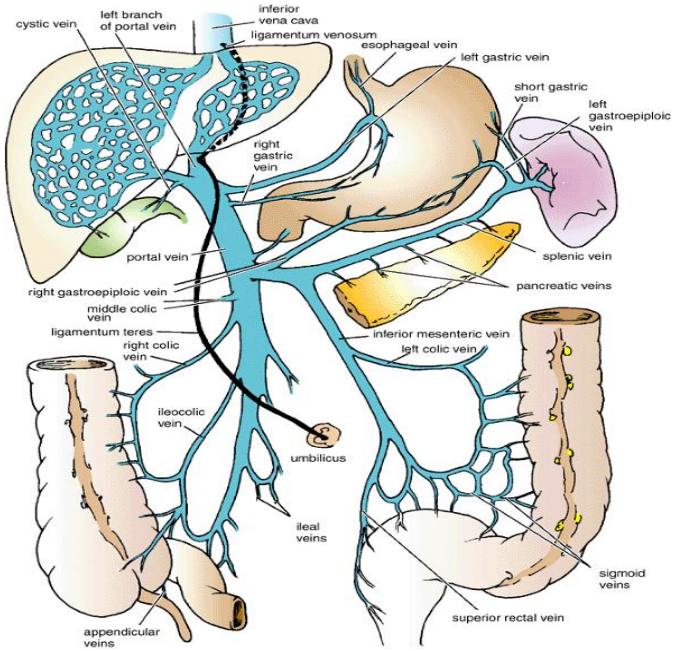

# Lymphatic Drainage of Rectum:

1. Lymph vessels from upper part accompany superior rectal artery to inferior mesenteric nodes.

2. Lymph vessels of lower part of rectum follow middle rectal artery to internal iliac nodes.

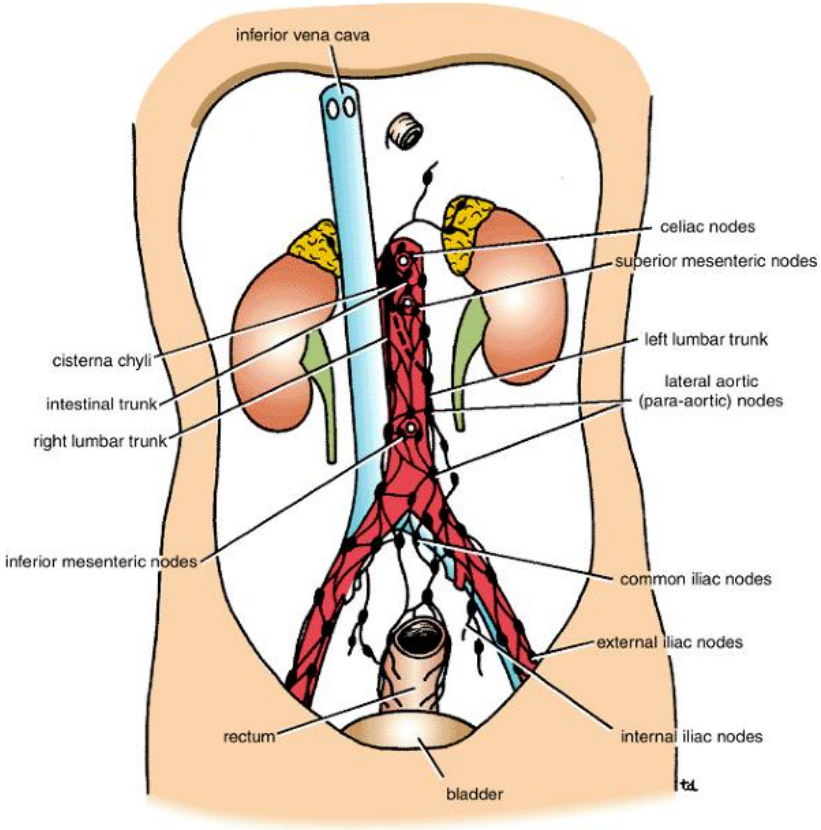

## Nerve Supply of Retum:

- **Sympathetic and parasympathetic nerves fron inferior hypogastric plexuses**
- ***The rectum is only sensitive to stretch.***

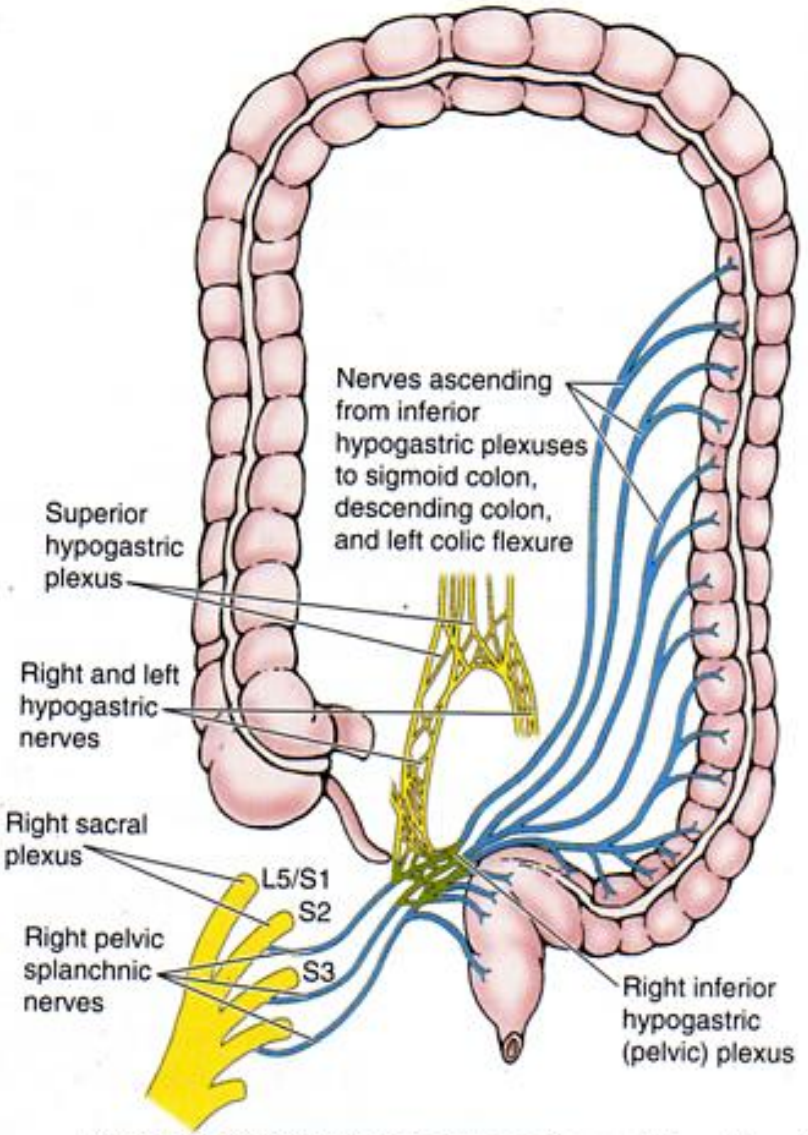


Parasympathetic nerves to descending and sigmoid colon

# ANAL CANAL

- About 1 ½ inches (4 Cm) long.

## Beginning of anal canal:

- Continuation of rectal ampulla.
- At anorectal junction.
- 1 inch in front of tip of coccyx.

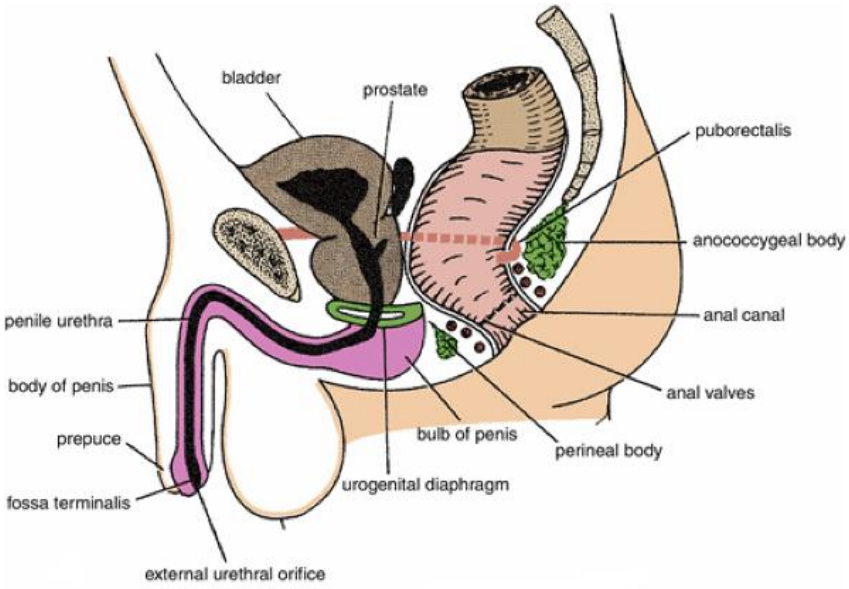


## End of anal canal: Anus

## Notes:

- Anal canal passes downward and backward
- Except during defecation, its lateral walls are kept in apposition by levatores ani muscles and anal sphincters.

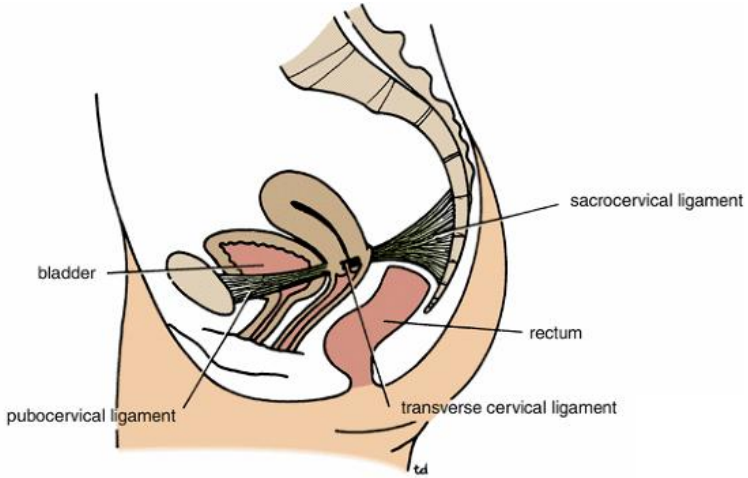

## Structure, blood supply, nerve supply and lymphatic drainage of anal canal:

### Mucous membrane of upper half of anal canal:

- Derived from hindgut endoderm
- Lined by columnar epithelium
- Thrown into vertical folds, anal columns, joined together at lower ends by semilunar folds, anal valves.

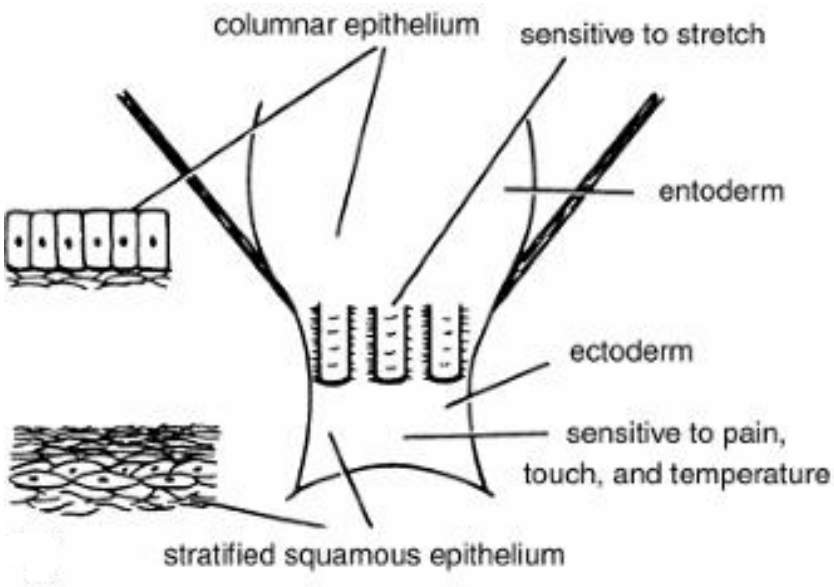


### Mucous membrane of lower half of anal canal:

- Derived from ectoderm of proctodeum
- Lined by stratified squamous epithelium, merges at anus with perianal epidermis.
- There are no anal columns.

## Arterial Supply of Upper Half of Anal Canal:

- Superior rectal artery (inferior mesenteric artery).

## Arterial Supply of Lower Half of Anal Canal:

- Inferior rectal artery (internal pudendal artery).

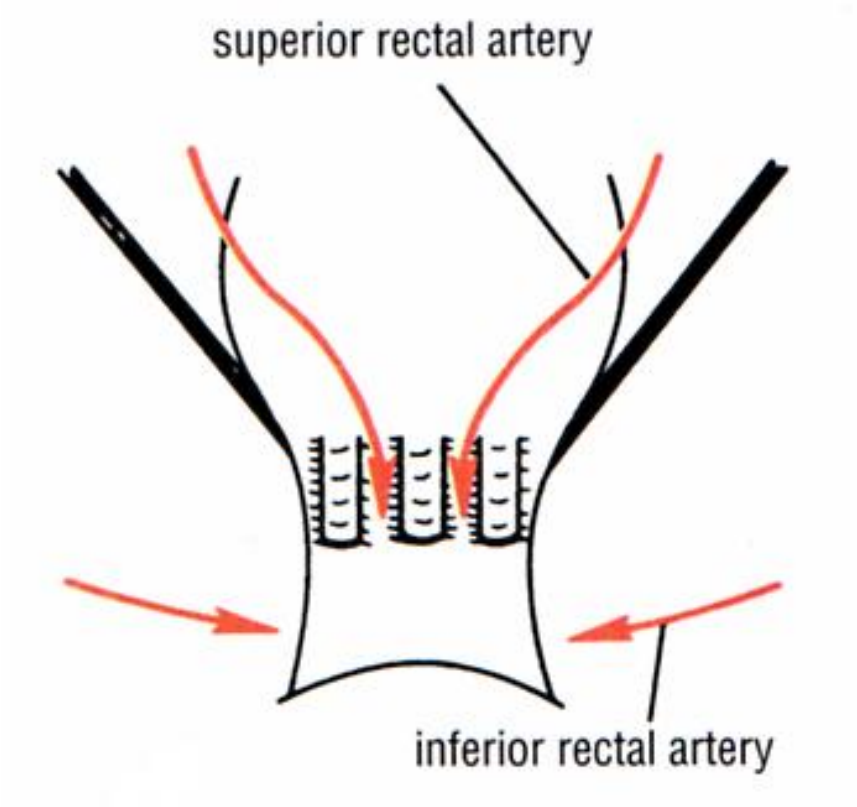

**Venous drainage of upper half of anal canal:**

**Superior rectal vein; inferior mesenteric vein (portal).**

**Venous drainage of lower half of anal canal:**

**Inferior rectal vein; internal pudendal vein, internal iliac vein (systemic).**

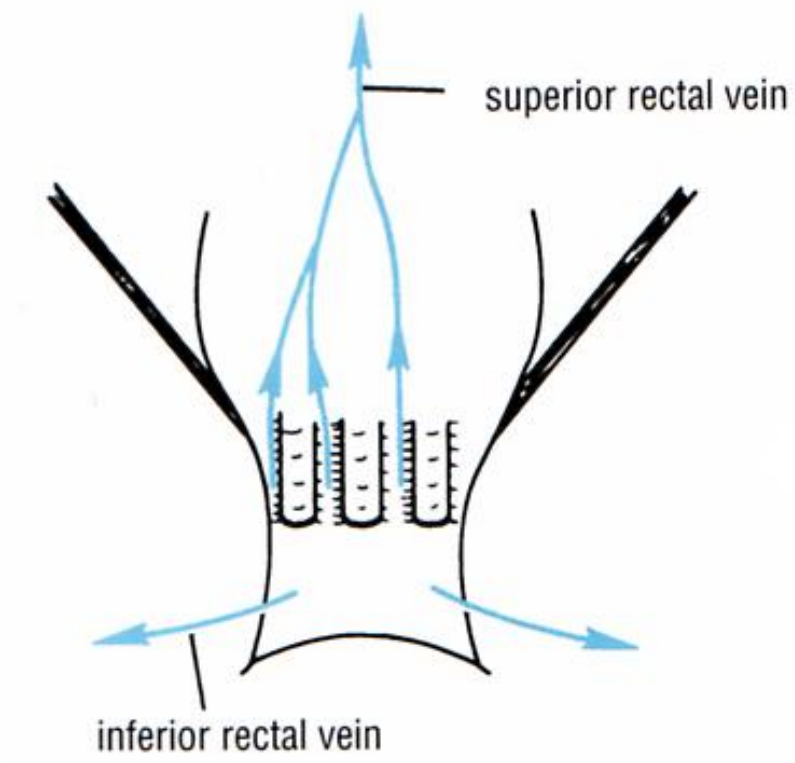

**Lymphatic Drainage of Upper Half of Anal Canal:** **Superior rectal artery to pararectal nodes and then to inferior mesenteric nodes.**

**Lymphatic Drainage of Lower Half of Anal Canal:** **Medial group of superficial inguinal nodes.**

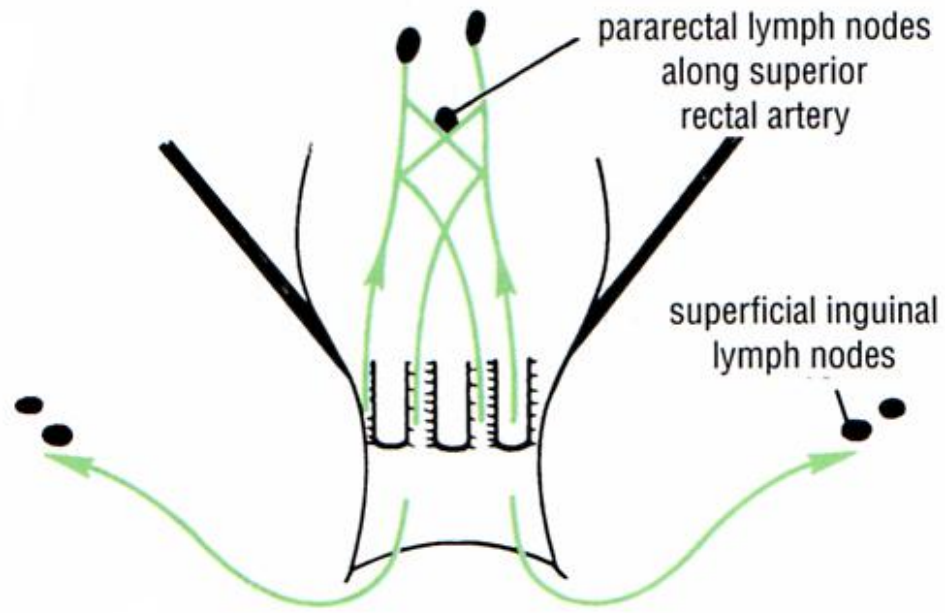

**Nerve Supply of Upper Half of Anal Canal:**

- **Autonomic hypogastric plexuses, sensitive only to stretch.**

**Nerve Supply of Lower Half of Anal Canal:**

- **Somatic inferior rectal nerve, sensitive to pain, temperature, touch and pressure.**

## Anal Sphincters:

## Internal Sphincter:

- Involuntary.
- Thickening of smooth muscle of circular coat at upper end of anal canal.
- Enclosed by sheath of stripped muscle that form voluntary external sphincter.

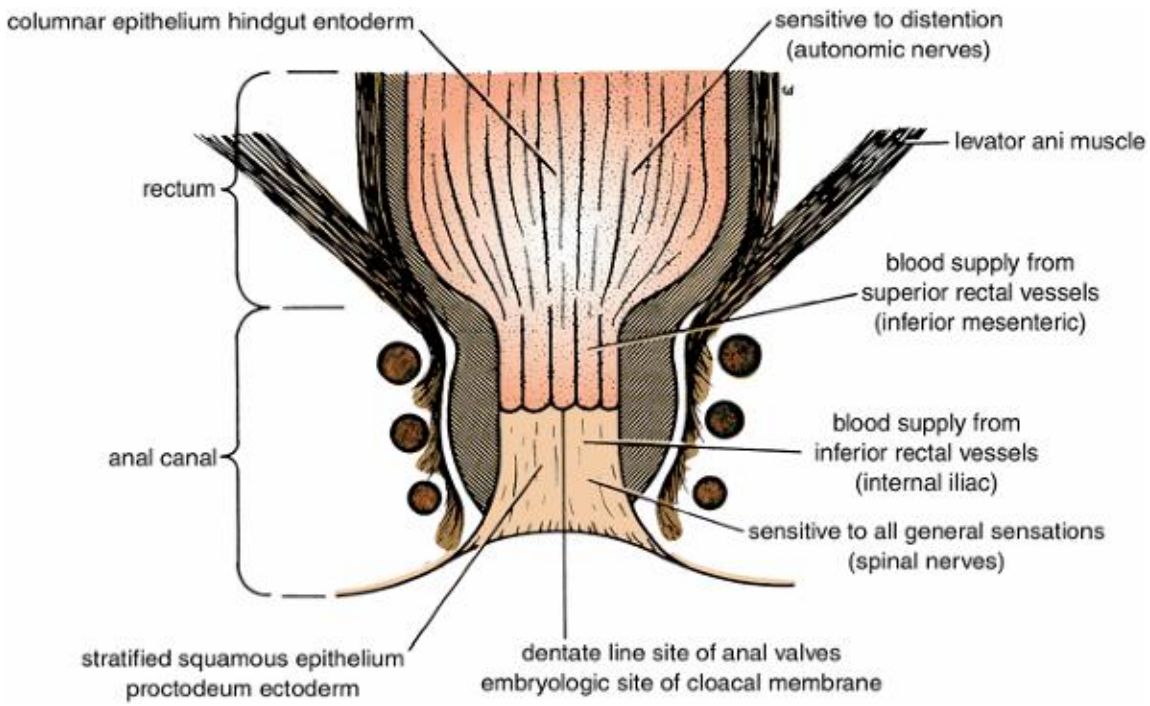

## II. External sphincter of anal canal:

## Can be divided into:

1. **Subcutaneous part: Encircles lower end of anal canal and has no bony attachments.**

2. **Superficial part: Attached to the coccyx (behind) and perineal body (front).**

3. **Deep part: Encircles upper end of anal canal and has no bony attachments.**

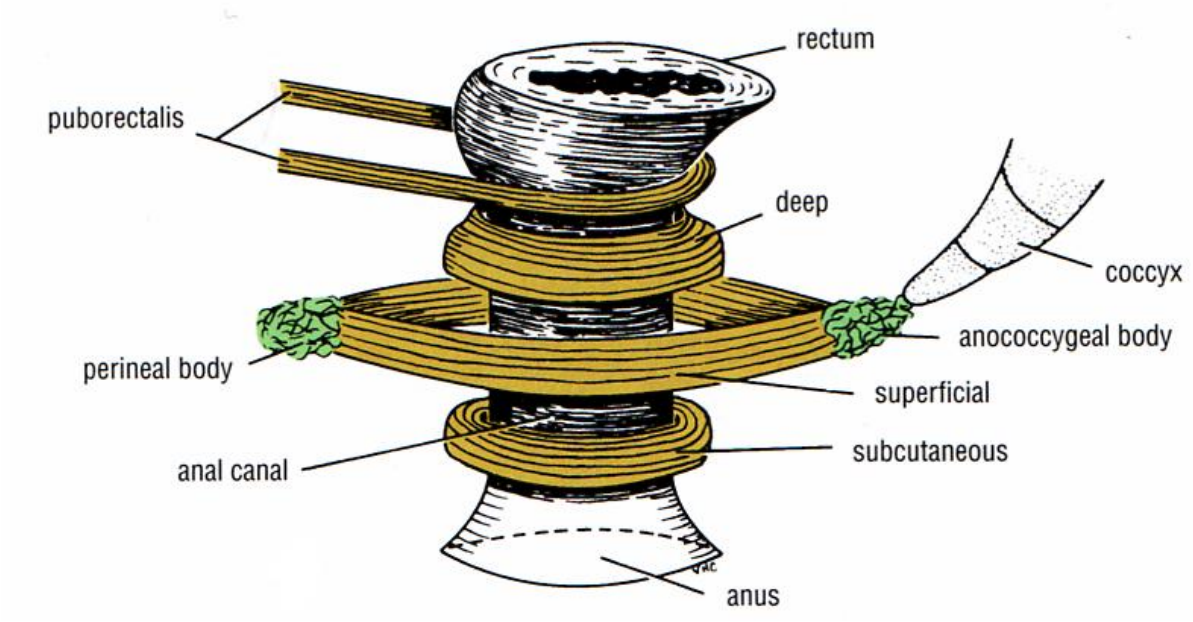

## Nerve Supply of Anal Canal:

### Involuntary internal sphincter:

- Sympathetic fibers from inferior hypogastric plexuses.

### Voluntary external sphincter:

1. Inferior rectal nerve (pudendal nerve).
2. Perineal branch of 4th sacral nerve.

# DIFFERENCES BETWEEN SMALL AND LARGE INTESTINE

## External differences between small and large intestine:

- **Longitudinal muscle of small intestine forms continuous layer around the gut, whereas that of large intestine, collected into 3 bands, taeniae coli**
- **Small intestine has no peritoneal tags attached to its wall, whereas large intestine has fatty tags; appendices epiploicae.**
- **Wall of small intestine is smooth, whereas that of large intestine is sacculated.**

## Internal differences between small and large intestine:

1. **Mucous membrane of small intestine has; plicae circulares, which are absent in large intestine.**
2. **Mucous membrane of small intestine has villi which are absent in large intestine.**
3. **Aggregations of lymphoid tissue; Peyer's patches are found in small intestine, they are absent in large intestine.**

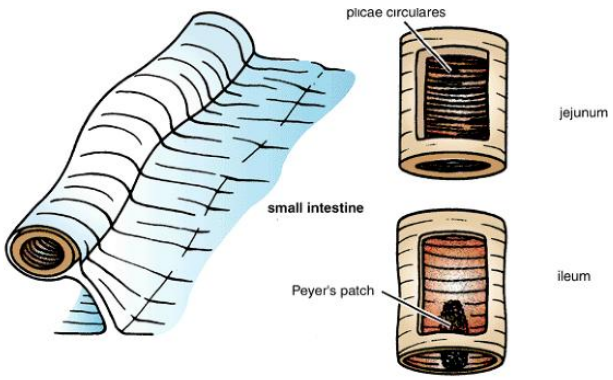


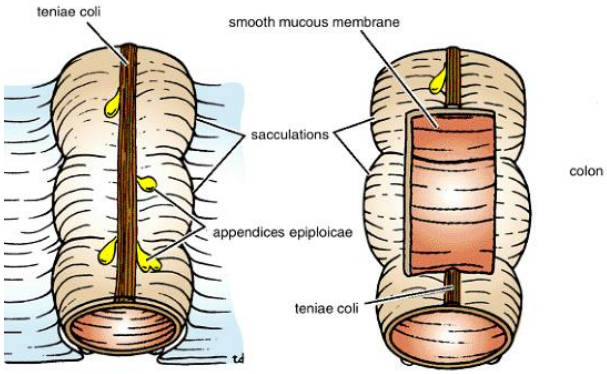

# Differences Between the Small and Large Intestine

| | Small intestine | Large intestine |
|---|---|---|
| Length | About long 6-7 meters | About long 1.5 meters |
| Caliber | Smaller | Larger |
| Mobility | Freely mobile | Less freely mobile |
| Teniae coli (3 bands of longitudinal muscles) | Absent | Present |
| Sacculations | Absent | Present |
| Appendices epiplica (fat ) | Absent | Present over free surface of colon except caecum, appendix and rectum |
| Mucous membrane | Has permanent folds, called plicae circulares | Absent |
| Villi in mucosa | Present | Absent |
| Peyer's patches (lymphatic aggregations) | Present | Absent |

# THANK YOU

*Prof Dr Mohamed El-Badry Mohamed*